

Histoplasmosis overlapping with HIV and tuberculosis in sub-Saharan Africa: challenges and research priorities

Marius Paulin Ngouanom Kuate, Bassey Ewa Ekeng, Richard Kwizera, Christine Mandengue and Felix Bongomin 

Abstract: Histoplasmosis, tuberculosis and HIV are all highly prevalent in sub-Saharan Africa (SSA). Co-occurrence of two or more of these infections has been reported in several populations of patients, especially those with advanced HIV infection where these opportunistic infections contribute to a significant morbidity and mortality. With a high burden of pulmonary tuberculosis (PTB) secondary to HIV in SSA, histoplasmosis is commonly misdiagnosed as smear-negative PTB in HIV patients due to similar clinical and radiological presentations. This is also partly the result of the lack of trained clinical and laboratory personnel to make a definite diagnosis of histoplasmosis. There is a low index of clinical suspicion for histoplasmosis, and cases are mostly discovered accidentally and documented through case reports and case series. Similarly, the high cost and lack of fungal diagnostics in most SSA countries makes it difficult to make a diagnosis. There is a need to build local capacity for mycology so that patients are managed to improve on the index of clinical suspicion and diagnostic capabilities. Moreover, simple accurate point-of-care diagnostic tests and first-line antifungal treatment for histoplasmosis are not available in many SSA countries. This review describes the existence of co-infections of histoplasmosis, tuberculosis and HIV in SSA, highlighting the challenges and research priorities.

Keywords: histoplasmosis, HIV, sub-Saharan Africa, tuberculosis

Received: 28 January 2021; revised manuscript accepted: 20 March 2021.

Histoplasmosis in sub-Saharan Africa

Histoplasmosis is an endemic invasive mycosis and a cause of morbidity in patients living in endemic areas. It is an important opportunistic infection in patients living with advanced human immunodeficiency virus (HIV) infection.¹ *Histoplasma* thrives in slightly alkaline soil containing bird or bat droppings.² Human histoplasmosis is an infection caused by inhalation of spores of a fungus called *Histoplasma capsulatum* which exists in two varieties, *Histoplasma capsulatum* var. *capsulatum* (Hcc) and *Histoplasma capsulatum* var. *duboisii* (Hcd), the latter known as African histoplasmosis.^{3,4} The first geographic distribution of *Histoplasma* was described in the 1940s in the United States of America (USA).⁵

Histoplasmosis is endemic in the central and eastern states of the USA, around the Ohio and Mississippi river valley, but also in parts of central and South America, southern and sub-Saharan Africa, India, China, and Southeast Asia.⁵ Cases are also seen throughout Europe and in non-endemic regions of the USA, often due to migration and travelers.^{6,7} From 1952 to 2017 the highest number of cases of histoplasmosis recorded in Africa was from West Africa followed by Southern Africa.⁸ Both Hcc and Hcd are widely distributed in sub-Saharan Africa.⁹

Transmission of the disease can also be through organ transplantation, but the majority of cases occur through inhalation of spores of the fungus

Ther Adv Infectious Dis

2021, Vol. 8: 1–7

DOI: 10.1177/
20499361211008675

© The Author(s), 2021.
Article reuse guidelines:
sagepub.com/journals-
permissions

Correspondence to:
Felix Bongomin
Department of Medical
Microbiology and
Immunology, Faculty of
Medicine, Gulu University,
P.O. Box 166, Gulu,
Uganda
drbongomin@gmail.com

**Marius Paulin
Ngouanom Kuate**
Department of
Microbiology and
Parasitology, Faculty of
Science, University of
Buea, Buea, Cameroon

Bassey Ewa Ekeng
Department of Medical
Microbiology &
Parasitology, University of
Calabar Teaching Hospital,
Calabar, Nigeria

Richard Kwizera
Translational Research
Laboratory, Department
of Research, Infectious
Diseases Institute, College
of Health Sciences,
Makerere University,
Kampala, Uganda

Christine Mandengue
Department of Internal
Medicine, Dermatology
Unit, Université des
Montagnes, Bangangte,
Cameroon

consequent to soil disruption, such as cave excavation.¹⁰ Human–human or animal–human transmission is not possible.⁶ *Histoplasma* is a thermally dimorphic ascomycete, displaying a filamentous mold form in the environment and in culture at temperatures below 35°C, and a yeast phase in tissue and body fluids at temperatures above 35°C. The mold phase may contain macroconidia and microconidia.¹¹ The dissemination of the disease occurs after inhalation of microconidia. After escaping the initial neutrophils, the microconidia will transform into narrow-based budding yeast and be ingested by the phagocytes. The phagocytized yeasts are transported to the lymph nodes and, if not eliminated due to a low inflammatory immune response, as in immunocompromised individuals, they enter the blood stream and spread throughout the body, causing disseminated disease.^{6,10–12}

Exposure to *Histoplasma* is frequent in endemic areas, with common asymptomatic cases.⁴ Subclinical histoplasmosis can be revealed through histoplasmin skin test reactivity.⁸ However, this test cannot distinguish between a current and a past infection.⁹ A number of studies have revealed positive histoplasmin skin sensitivity in Africa, with the prevalence varying from 0.0% to 28%.⁹ A recent histoplasmin skin sensitivity survey done in Nigeria reported a positive rate of 4.4%.⁸ Similar histoplasmin skin sensitivity prevalence of 3.8% was noted among community subjects in Uganda.¹³

The most at-risk populations include persons exposed to large inoculum, immunocompromised patients, extremes of age and underlying emphysema. Aged smokers are more predisposed to chronic pulmonary disease. Disseminated progressive disease is commonly seen in persons with cell-mediated immunological defects like hematological malignancies, HIV, transplant recipients and prolonged use of corticosteroids. Exposure to *H. capsulatum* does not confer immunity to reinfection. The lungs are the first site of infection before hematogenous dissemination. Following inhalation of spores, *H. capsulatum* causes a wide spectrum of asymptomatic pulmonary infection, to acute or chronic disease of the lungs, or more disseminated disease in immunocompromised individuals.¹⁴ Therefore, clinical presentations vary depending on the immune status of the host and the infectious dose. In most cases histoplasmosis presents as a mild respiratory tract syndrome.

However, symptoms such as chest pain, fever, cough, chills, myalgia, headache and anorexia may occur in the more heavily exposed individuals. The patient may be left with a positive serology and calcifications may be seen in spleen, liver, lungs, and lymph nodes years later.¹⁴ Pulmonary histoplasmosis is classified into: (1) acute pulmonary histoplasmosis, (2) chronic cavitary pulmonary histoplasmosis, and (3) progressive disseminated histoplasmosis.

The aim of this paper is to describe the existence of co-infections of histoplasmosis, tuberculosis (TB) and HIV in sub-Saharan Africa, highlighting the challenges and research priorities.

Tuberculosis and histoplasmosis in sub-Saharan Africa

TB is a public health problem with increased occurrence in people living with HIV and AIDS, with case rates increasing by an average of 7% per year after 1985 in 20 sub-Saharan African countries.¹⁵ About 1.2 million new cases of TB were reported amongst people living with HIV in 2016, 71% of whom were living in Africa.¹⁶ In highly TB-burdened countries, more than 75% of TB cases are HIV associated.¹⁷ Compared with HIV-uninfected persons, HIV-infected persons are 26–31 times more likely to develop active TB,¹⁶ with a case fatality rate of 16–35%, which is almost four times higher than HIV-free individuals.¹⁸ In 2003, a comparison of HIV prevalence in general populations and TB patients revealed the incidence of TB to be 8.3 times higher in HIV-positive than HIV-negative African people.¹⁷ The rate of recurrent TB is also increased in HIV patients either through endogenous reactivation or exogenous reinfection.¹⁹ The incidence rate of TB in sub-Saharan Africa is growing at a rate faster than any other region globally, approximately at a rate of 4% per year.¹⁹ Advanced HIV disease (AHD) patients may develop several opportunistic infections depending on their CD4 counts. The risk of multiple infections increases with lower CD4 counts. Co-occurrence of TB with histoplasmosis has been reported in several populations of patients with advanced HIV from Latin American countries^{20–22} and sub-Saharan Africa.²³ Both clinical conditions are opportunistic infections commonly identified in patients with advanced HIV.²⁴ The principal challenge in identifying and managing pulmonary histoplasmosis is its clinical similarity with pulmonary TB. Some of the smear

(and culture or GeneXpert)-negative cases of pulmonary TB in sub-Saharan Africa may be cases of pulmonary histoplasmosis misdiagnosed as TB. Two cases of histoplasmosis misdiagnosed as miliary TB were reported by Schouten and colleagues in an international group of students who attended a field course on tropical ecology in Kibale forest, National park, Uganda.²⁵ In a yet-to-be-published study by Ekeng *et al.*²³ on the prevalence of histoplasmosis in patients with presumptive pulmonary TB detected by urinary histoplasma galactomannan enzyme immunoassay and sputum PCR, the rate of histoplasmosis and co-occurrence of TB/histoplasmosis among AHD patients was 9.76% and 7.32%, respectively, while the prevalence rate in presumptive TB patients with negative acid-fast bacilli/GeneXpert and HIV serology results was 20.51%. In yet another study, by Darré *et al.*,²⁶ 17 cases of African histoplasmosis were reported of which three were from HIV patients. Misdiagnosis of histoplasmosis and TB/histoplasmosis co-occurrences is still a major issue in the management of patients presenting with symptoms suggestive of such, likely due to inadequate awareness, a low index of suspicion from the clinicians, and the lack of diagnostic tools.²⁷ Both scenarios may ultimately result in prolonged hospital stay, economic losses, misuse of antimicrobials, and mortalities.^{27,28} A review by Mandengue *et al.*²⁷ revealed nine reported case patients, initially diagnosed and unsuccessfully treated for TB, with disseminated histoplasmosis detected at a late stage. Of the nine patients four died, two were diagnosed at post mortem, two recovered, and the outcome was unknown in one of the case patients. Co-occurrence of TB/histoplasmosis infections is often characterized by persistence of symptoms despite completion of anti-Koch's regimen in a patient with confirmed TB, with a late detection of histoplasmosis.²⁸ Continued advocacy, improved awareness, especially on the part of the clinicians, and funding are very important tools that must be consistently utilized to tackle these challenges.

Histoplasmosis and HIV in sub-Saharan Africa

At the end of 2017, 36.9 million people were living with HIV worldwide, sub-Saharan Africa accounting for 69%.²⁹ Despite efforts made to eradicate the disease, this number increased to 38.0 million globally and 25.6 million in sub-Saharan Africa at the end of 2019.³⁰ Moreover, in

2019, 690,000 worldwide and 440,000 from sub-Saharan Africa still died from AIDS-related illness.³⁰ The leading cause of deaths among people living with HIV (PLHIV) still remains TB,³¹ but diseases, including histoplasmosis, are important cause of deaths in PLHIV.²⁴

Progressive disseminated histoplasmosis usually occurs in the immunocompromised patients, especially in the HIV-positive population, due to failure of cell-mediated immunity. It is mostly seen in patients with a CD4 T-cell count of less than 150 cells per microliter. Although disseminated histoplasmosis can be reported in immunocompetent patients, it is an AIDS-defining infection,³² with a high mortality and morbidity in HIV-positive patients.^{33,34} Any body organ can be affected, but it is mostly seen in the lung, liver, spleen, brain and adrenals.³⁵ A review on histoplasmosis in Africa by Oladele *et al.* showed 470 cases of histoplasmosis reported in Africa over the last six decades, with HIV-infected patients accounting for 38% (178) of the cases⁸ (Figure 1).

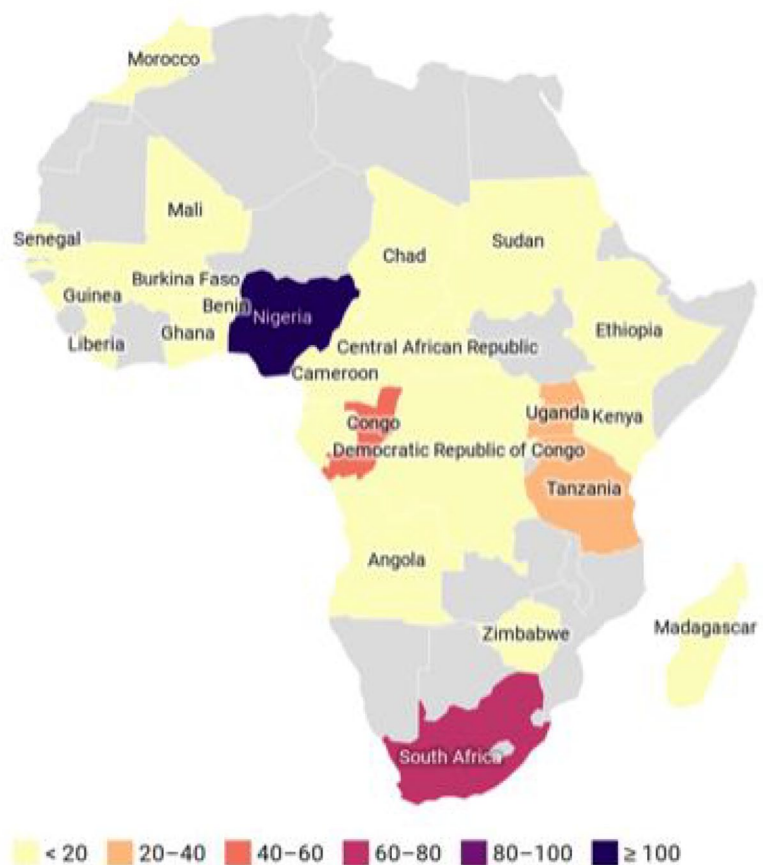

Figure 1. Published cases of histoplasmosis in Africa.^{8,36}

Table 1. Estimated burden of histoplasmosis in some countries in sub-Saharan Africa.

Country	Burden	Rate/100 K	Group at risk	Prevalence used for estimation	Reference
Cameroon	1800	16	HIV/AIDS	1.5% over 2 years in patients with CD4 counts $<200 \times 10^6/\text{mL}$	Mandengue and Denning ³⁷
Tanzania	135	0.31	None	0.9%	Faini <i>et al.</i> ⁴⁰
Ghana	724	2.5	HIV/AIDS	/	Ocansey <i>et al.</i> ³⁹
South Africa	60	0.1	HIV/AIDS	/	Schwartz <i>et al.</i> ³⁸
Mozambique	153	0.6	HIV/respiratory disease	58%	Sacarlal and Denning ⁴¹

Data about burden estimates and epidemiological studies for histoplasmosis are limited in sub-Saharan Africa (Table 1). A 13% prevalence of histoplasmosis was reported by Mandengue and Denning in Yaoundé in 2015.³⁷ The burden of histoplasmosis was estimated in South Africa, Cameroon, Tanzania and Ghana.^{38–41} More research is needed to determine the actual burden of histoplasmosis among the HIV population in sub-Saharan Africa.

Research trends and challenges in Africa

First and foremost, there is a significant knowledge gap on all aspects of histoplasmosis among clinicians and laboratorians alike in sub-Saharan Africa that urgently needs to be addressed. This is in addition to the challenge of lack of skilled personnel and infrastructure. Data on African histoplasmosis remain scarce in sub-Saharan Africa. Pulmonary disease is rare in this form of histoplasmosis. It involves mainly skin, bone and subcutaneous tissues.

In sub-Saharan Africa, there is a low index of clinical suspicion for histoplasmosis, and cases are mostly discovered accidentally and documented through case reports and case series.^{42,43} In Lomé, 17 cases were reported from 2002 to 2016.²⁶ In a similar study in Kimpese, Democratic Republic of the Congo, 36 patients were infected with Hcd.⁴⁴ Case reports have been published across sub-Saharan Africa in recent years.^{8,45} Some cases are diagnosed by histopathology using biopsy or autopsy samples.³⁶ Most patients present with nodular cystic swellings, and histology reveals a chronic granulomatous inflammatory reaction with foreign body giant cells containing large fungal spores. Histopathology may also rarely show

bone involvement. Skin manifestations of histoplasmosis are misdiagnosed as cryptococcal skin lesions, common in patients with AIDS. With the high burden of pulmonary TB secondary to HIV in sub-Saharan Africa, histoplasmosis is commonly misdiagnosed as smear-negative pulmonary TB in HIV patients due to similar clinical and radiological presentations.⁸ This is also partly because of the lack of trained clinical and laboratory personnel to make a definite diagnosis.

Similarly, the high cost and lack of fungal diagnostics in most sub-Saharan Africa countries make it difficult to make a diagnosis. Among the tests used for histoplasmosis (culture-based methods, serological methods, microscopy, antigen-detection methods and molecular-based methods),^{1,46} antigen-detection and molecular-based methods are not available in most countries.^{46,47} There is an urgent need to put in place simple rapid diagnostic techniques for histoplasmosis in sub-Saharan Africa countries, where the disease is still underdiagnosed.¹¹ Training to bridge the gap in knowledge on the prevention, diagnosis, and treatment of histoplasmosis amongst health workers is the first step to build capacity in African countries. There is need to build laboratory capacity and improve the availability and affordability of diagnostics, and train laboratory technologists and clinicians in fungal disease diagnosis and treatment.

Most histoplasmosis cases go untreated due to failure to make a diagnosis, or are empirically treated as smear-negative TB. Besides, even with a correct diagnosis, itraconazole and amphotericin B, which are the drugs of choice for management of histoplasmosis, are not readily available in most African countries. The generic

brands for these first-line antifungals for histoplasmosis are not affordable for most of the citizens in sub-Saharan Africa in particular,⁴⁸ though they are on the World Health Organization's essential medicine list.⁴⁹

A lot of work in terms of empirical research needs to go in programmatic surveys for subclinical histoplasmosis infection through histoplasmin skin tests, in addition to targeted screening of patients, especially persons with HIV with chronic cough, and smear-negative TB patients.

Currently, none of the antigen or antibody tests for histoplasmosis has been validated in Africa. This is an area of further research to drive accurate and early diagnosis of this disease. Also, we need to identify barriers to and facilitators of histoplasmosis treatment access and availability in the continent. Moreover, there is no standardized treatment for histoplasmosis based on randomized clinical trials on the continent.

Conclusions

Histoplasmosis in an AIDS-related illness still largely underdiagnosed in sub-Saharan Africa. More research is needed to determine the actual burden of this potentially life-threatening illness. There is the need to build local capacity for mycology in sub-Saharan Africa so that patients are managed appropriately, and to improve on the index of clinical suspicion and diagnostic capabilities. Pulmonary histoplasmosis may be misdiagnosed as smear-negative TB. Moreover, simple, accurate diagnostic techniques and first-line treatment for histoplasmosis are not available in many sub-Saharan Africa countries. Strategies need to be put in place by the Pan African Mycology Working Group through the different governments and international health organizations to address the situation.

Author contributions

Felix Bongomin conceptualized the study. Marius Paulin Ngouanom Kuate, Bassey Ewa Ekeng, Richard Kwizera, Christine Mandengue and Felix Bongomin contributed to the drafting of the manuscript. All authors reviewed and approved the final manuscript prior to submission.

Funding

The authors disclosed receipt of the following financial support for the research, authorship,

and/or publication of this article: Felix Bongomin research work is supported by the Forgyarty International Centre of the National Institutes of Health under Award Number D43 TW011401. The content is solely the responsibility of the authors and does not necessarily represent the official views of the National Institutes of Health.


Conflict of interest statement

The authors declare that there is no conflict of interest.

Ethical statement

Our study did not require an ethical board approval because of its design of literature review of published data. Our study did not require consent because no individual patient data was included.

ORCID iD

Felix Bongomin  <https://orcid.org/0000-0003-4515-8517>

References

1. Azar MM and Hage CA. Laboratory diagnostics for histoplasmosis. *J Clin Microbiol* 2017; 55: 1612–1620.
2. Sipsas NV and Kontoyiannis DP. Occupation, lifestyle, diet and invasive fungal infections. *Infection* 2008; 36: 515–525.
3. Loulergue P, Bastides F, Baudouin V, *et al.* Literature review and case histories of *Histoplasma capsulatum* var. *duboisii* infections in HIV-infected patients. *Emerg Infect Dis* 2007; 13: 1647–1652.
4. Muotoe-Okafor FA, Gugnani HC and Gugnani A. Skin and serum reactivity among humans to histoplasmin in the vicinity of a natural focus of *Histoplasma capsulatum* var. *duboisii*. *Mycopathologia* 1996; 134: 71–74.
5. Bahr NC, Antinori S, Wheat LJ, *et al.* Histoplasmosis infections worldwide: thinking outside of the Ohio River Valley. *Curr Trop Med Rep* 2015; 2: 70–80.
6. Center for Disease Control and Prevention. Histoplasmosis, <https://www.cdc.gov/fungal/diseases/histoplasmosis/index.html> (2018, accessed 4 March 2021).
7. Scully MC and Baddley JW. Epidemiology of histoplasmosis. *Curr Fungal Infect Rep* 2018; 12: 51–58.
8. Oladele RO, Ayanlowo OO, Richardson MD, *et al.* Histoplasmosis in Africa: an emerging or a

- neglected disease? *PLoS Negl Trop Dis* 2018; 12: e0006046.
9. Gugnani HC. Histoplasmosis in Africa: a review. *Indian J Chest Dis Allied Sci* 2000; 42: 271–277.
 10. Dighe NS, Pattan SR, Bhawar SB, *et al.* Darling's disease: a review. *J Chem Pharm Res* 2009; 1: 88–101.
 11. Adenis AA, Aznar C and Couppié P. Histoplasmosis in HIV-infected patients: a review of new developments and remaining gaps. *Curr Trop Med Rep* 2014; 1: 119–128.
 12. Myint T, Leedy N, Villacorta Cari E, *et al.* HIV-associated histoplasmosis: current perspectives. *HIV/AIDS (Auckl)* 2020; 12: 113–125.
 13. Bezjak V and Farsey SJ. Prevalence of skin sensitivity to histoplasmin and coccidioidin in various Ugandan populations. *Am J Trop Med Hyg* 1970; 19: 664–669.
 14. Inojosa W, Rossi MC, Laurino L, *et al.* Progressive disseminated histoplasmosis among human immunodeficiency virus-infected patients from West-Africa: report of four imported cases in Italy. *Infez Med* 2011; 19: 49–55.
 15. Adeiza MA, Abba AA and Okpapi JU. HIV-associated tuberculosis: a sub-Saharan African perspective. *Sub-Saharan Afr J Med* 2014; 1: 1–14.
 16. Gelaw YA, Williams G, Soares Magalhães RJ, *et al.* HIV prevalence among tuberculosis patients in sub-Saharan Africa: a systematic review and meta-analysis. *AIDS Behav* 2019; 23: 1561–1575.
 17. Corbett EL, Marston B, Churchyard GJ, *et al.* Tuberculosis in sub-Saharan Africa: opportunities, challenges, and change in the era of antiretroviral treatment. *Lancet* 2006; 367: 926–937.
 18. Teweldemedhin M, Asres N, Gebreyesus H, *et al.* Tuberculosis-Human Immunodeficiency Virus (HIV) co-infection in Ethiopia: a systematic review and meta-analysis. *BMC Infect Dis* 2018; 18: 676.
 19. Maher D, Harries A and Getahun H. Tuberculosis and HIV interaction in sub-Saharan Africa: impact on patients and programmes; implications for policies. *Trop Med Intern Health* 2005; 10: 734–742.
 20. López Daneri AG, Arechavala A, Iovannitti CA, *et al.* Histoplasmosis diseminada en pacientes HIV/SIDA: Buenos Aires, 2009–2014. *Medicina* 2016; 76: 332–337.
 21. Boigues BCS, Paniago AMM, Lima GME, *et al.* Clinical outcomes and risk factors for death from disseminated histoplasmosis in patients with AIDS who visited a high-complexity hospital in Campo Grande, MS, Brazil. *Rev Soc Bras Med Trop* 2018; 51: 155–161.
 22. Caceres DH, Tobon AM, Cleveland AA, *et al.* Clinical and laboratory profile of persons living with human immunodeficiency virus/acquired immune deficiency syndrome and histoplasmosis from a Colombian hospital. *Am J Trop Med Hyg* 2016; 95: 918–924.
 23. Ekeng BE, Oladele RO, Emanghe UE, *et al.* Prevalence of histoplasmosis in patients with presumptive pulmonary tuberculosis in University of Calabar teaching hospital, Calabar (unpublished manuscript). Calabar: Department of Medical Microbiology and Parasitology, University of Calabar Teaching Hospital, 2021.
 24. Caceres DH and Valdes A. Histoplasmosis and tuberculosis co-occurrence in people with advanced HIV. *J Fungi (Basel)* 2019; 5: 73.
 25. Schouten R, Verheul J and Griethuysen A. An outbreak of histoplasmosis misdiagnosed as miliary tuberculosis among participants of a tropical biology course in Uganda. Poster presentation: American society of Tropical Medicine and Hygiene 51st Annual Meeting, 11–15 November 2012, Atlanta, GA.
 26. Darré T, Saka B, Mouhari-Touré A, *et al.* Histoplasmosis by *Histoplasma capsulatum* var. *duboisii* observed at the laboratory of pathological anatomy of Lomé in Togo. *J Pathog* 2017; 2017: 2323412.
 27. Mandengue CE, Ekeng BE and Oladele RO. Disseminated histoplasmosis; a threat in advanced HIV disease population in sub-Saharan Africa? *J Adv Med Med Res* 2021; 33: 115–144.
 28. Gonçalves D, Ferraz C and Vaz L. Posaconazole as rescue therapy in African histoplasmosis. *Braz J Infect Dis* 2013; 17: 102–105.
 29. UN Joint Programme on HIV/AIDS (UNAIDS). *UNAIDS report on the global AIDS epidemic*. Global report. New York, NY: UN, 2018.
 30. UN Joint Programme on HIV/AIDS (UNAIDS). *UNAIDS report on the global AIDS epidemic*. Global report. New York, NY: UN, 2020.
 31. Avert. Global HIV and aids statistics, <https://www.avert.org/global-hiv-and-aids-statistics> (2020, accessed 4 March 2021).
 32. Kriplani DM, Kante KA, Maniar JK, *et al.* Histoplasmosis in an immunocompetent host:

- a rare case report. *Int J Res Med Sci* 2017; 5: 1148–1150.
33. Oladele RO, Toriello C, Ogunsola FT, *et al.* Prior subclinical histoplasmosis revealed in Nigeria using histoplasmin skin testing. *PLoS One* 2018; 13: e0196224.
 34. Baker J, Kosmidis C, Rozaliyani A, *et al.* Chronic pulmonary histoplasmosis – a scoping literature review. *Open Forum Infect Dis* 2020; 7: ofaa119.
 35. Tsiodras S, Drogari-Apiranthitou M, Pilichos K, *et al.* An unusual cutaneous tumor: African histoplasmosis following mud baths: case report and review. *Am J Trop Med Hyg* 2012; 86: 261–263.
 36. Kwizera R, Bongomin F and Lukande R. Deep fungal infections diagnosed by histology Uganda: a 70-year retrospective study. *Med Mycol* 2020; 58: 1044–1052.
 37. Mandengue C and Denning DW. The burden of serious fungal infections in Cameroon. *J Fungi (Basel)* 2018; 4: 44.
 38. Schwartz I, Boyles T, Kenyon C, *et al.* The estimated burden of fungal disease in South Africa. *S Afr Med J* 2019; 109: 885–892.
 39. Ocansey BK, Pesewu GA, Codjoe FS, *et al.* Estimated burden of serious fungal infections in Ghana. *J Fungi (Basel)* 2019; 5: 38.
 40. Faini D, Maokola W, Furrer H, *et al.* Burden of serious fungal infections in Tanzania. *Mycoses* 2015; 58: 70–79.
 41. Sacarlal J and Denning DW. Estimated burden of serious fungal infections in Mozambique. *J Fungi (Basel)* 2018; 4: 75.
 42. Oladele RO, Otu AA, Olubamwo O, *et al.* Evaluation of knowledge and awareness of invasive fungal infections amongst resident doctors in Nigeria. *Pan Afr Med J* 2020; 36: 297.
 43. Oladele RO and Denning DW. Burden of serious fungal infection in Nigeria. *West Afr J Med* 2014; 33: 107–114.
 44. Pakasa N, Biber A, Nsiangana S, *et al.* African histoplasmosis in HIV-negative patients, Kimpese, democratic republic of the congo. *Emerg Infect Dis* 2018; 24: 2068–2070.
 45. Minta DK, Sylla M, Traoré AM, *et al.* Première observation malienne d’histoplasmosse africaine disséminée à prédominance osseuse chez un enfant VIH négatif. *Revue de la littérature. J Mycol Med* 2014; 24: 152–157.
 46. Guimarães AJ, Nosanchuk JD and Zancopé-Oliveira RM. Diagnosis of histoplasmosis. *Braz J Microbiol* 2006; 37: 1–13.
 47. Mandengue CE, Ngandjio A and Atangana PJ. Histoplasmosis in HIV-infected persons, Yaoundé, Cameroon. *Emerg Infect Dis* 2015; 21: 2094–2096.
 48. Kneale M, Bartholomew JS, Davies E, *et al.* Global access to antifungal therapy and its variable cost. *J Antimicrob Chemother* 2016; 71: 3599–3606.
 49. Bongomin F, Govender NP, Chakrabarti A, *et al.* Essential in vitro diagnostics for advanced HIV and serious fungal diseases: international experts’ consensus recommendations. *Eur J Clin Microbiol Infect Dis* 2019; 38: 1581–1584.

Visit SAGE journals online
[journals.sagepub.com/
 home/tai](http://journals.sagepub.com/home/tai)

 SAGE journals