

# High Expression of WT1 and Low Expression of p53 in Archived Blocks of Children with Wilms Tumor in South Western Uganda

Brian Ssenkumba<sup>1</sup>, Barnabas Atwiine<sup>2,3</sup>, Yekosani Mitala<sup>1</sup>, Janet Adongo<sup>4</sup>, Samuel Olowo<sup>4</sup>, Rita Nabulya<sup>1</sup>, Amnia Diaz Anaya<sup>1</sup>, Raymond Atwine<sup>1</sup>

<sup>1</sup>Department of Pathology, Mbarara University of Science and Technology, Mbarara, Uganda; <sup>2</sup>Department of Paediatrics and Child Health, Mbarara University of Science and Technology, Mbarara, Uganda; <sup>3</sup>Department of Paediatrics and Child Health, Mbarara Regional Referral Hospital, Mbarara, Uganda; <sup>4</sup>Department of Nursing, Mbarara University of Science and Technology, Mbarara, Uganda

Correspondence: Brian Ssenkumba, Department of Pathology, Mbarara University of Science and Technology, P.O. BOX 1410, Mbarara, Uganda, Tel +256701364029, Email [ssenkumbabrianldp15@gmail.com](mailto:ssenkumbabrianldp15@gmail.com)

**Purpose:** The determination of the presence or absence of anaplasia in Wilms tumor is difficult sometimes creating diagnostic errors and is worsened by the use of neoadjuvant chemotherapy, which causes cellular alterations that may mimic anaplasia. This study described the histological features of Wilms tumor and their association with WT1 and p53 expression in archived specimens in South Western Uganda.

**Patients and Methods:** A series of 308 formalin-fixed paraffin-embedded tissue blocks belonging to 85 children were retrospectively recruited in the only public Histopathology laboratory in South Western Uganda. Rabbit monoclonal Anti-Wilms tumor protein antibody [(CAN-R9) IHC-56-2] ab89901 and rabbit monoclonal Anti-p53 antibody [E26] ab32389 were used to assess the expression of WT1 and p53, respectively. The expression of WT1 and p53 were reported as proportions, Chi-square was also performed to assess for associations and statistical significance was considered when the p-value was less than 0.05.

**Results:** The median age was 3.5 with an interquartile range of (2–6) years. Mixed histology was the most common at 35.29% (95% CI:25.77–46.14). Anaplasia was present in 5.88% (95% CI:2.44–13.52) of the specimens. p53 and WT1 expressions were 13.0% (95% CI:7.25–22.04), and 41.0% (95% CI: 31.11–52.04), respectively.

**Conclusion:** Mixed-type histology is the most common histologic feature of Wilms tumor with high expression of WT1 and a low expression of p53 implying that these can be used routinely to confirm the diagnosis as well as anaplasia in South Western Uganda.

**Keywords:** children, Wilms tumor, p53, WT1, South Western Uganda

## Introduction

Wilms tumor (WT), a cancer of the kidney is the commonest pediatric cancer in childhood and the commonest pediatric renal tumor globally, and the commonest solid tumor in Uganda.<sup>1–4</sup> Determination of the presence or absence of anaplasia in WT is difficult sometimes creating diagnostic errors. The use of neoadjuvant chemotherapy worsens this; it causes cellular alterations that may mimic anaplasia.<sup>5</sup> Research has already indicated that up to 39% of pathologists misclassified WT as having anaplasia<sup>6</sup> and a survey done at Mbarara Regional Referral Hospital (MRRH) pediatric oncology in 2021 revealed 22.2% of WT cases were reported as having anaplasia by pathologists which is twice the global average exposing children to unnecessary chemotherapy.<sup>4</sup> Immunohistochemical detection of p53 can be used as a surrogate marker for *TP53* mutation hence making determination of anaplasia easy.<sup>7</sup> In this study, we described WT histologic features and their association with the expression of p53 and WT1 in archived tissue blocks of children with a confirmed diagnosis of WT at Mbarara Regional Referral Hospital in South Western Uganda.

## Materials and Methods

### Study Design and Setting

This was a retrospective descriptive cross-sectional study conducted at the histopathology laboratory of Mbarara Regional Referral Hospital (MRRH). The laboratory handles over 5000 histology and 3000 cytology samples annually

from the entire South Western Uganda, neighboring districts, and countries like the Democratic Republic of Congo and Rwanda. The pathology department is competent staff and also equipped with a tissue embedding system, a modern microtome, an antiquated tissue processing device, and a manual slide staining and labeling operation.

## Study Population and Recruitment Process

The study included all accessible formalin-fixed paraffin-embedded (FFPE) blocks in the archive with a diagnosis of Wilms tumor from January 2011 to December 2022. A retrospective collection of patient demographics and retrieval of formalin-fixed paraffin-embedded blocks was done followed by histologic re-evaluation of the previous diagnosis. All cases with complete demographics and available blocks of good quality were included in the analysis. However, exhausted tissue blocks, those with only necrotic tumor, as well as those with missing demographics were excluded from this study.

## Sampling Method

A total of 85 patients with a confirmed histologic diagnosis of WT were included in the analysis. Sampling was done consecutively and all cases that met the inclusion criteria were included. The sample size was determined using finite population formulation by Daniel and Cross and a reference prevalence of 16.7% from a study done at the Uganda Cancer Institute.<sup>8,9</sup>

## Laboratory Processing

### Hematoxylin and Eosin Staining

All selected FFPE tissue blocks were sectioned at a thickness of 4 $\mu$ m and stained with hematoxylin and eosin. Histologic feature classification was based on the International Society of Pediatric Oncology (SIOP).<sup>10</sup> Anaplasia was defined as the presence of three morphologic characteristics: abnormal multipolar mitoses, hyperchromatic tumor cell nuclei, and markedly enlarged tumor cell nuclei. Epithelial predominant, blastemal predominant, and stromal predominant were defined by presence of more than 66% of the viable tumor cells with one of the above components, respectively, while mixed type histology was defined by tumors with either epithelial and blastemal, epithelial and stromal, blastemal and stromal, or presence of all the three components and none constitute more than 66% of the tumor following review of the sections stained by H&E.

### Immunohistochemical Staining for Immunohistochemical Expression of WT1 and p53

Selected tissue blocks were sectioned with at 4  $\mu$ m thickness, placed on charged microscope slides, and dried in a tissue-drying oven for 45 minutes at 60°C. Sections were deparaffinized in 3 changes of xylene for 5 minutes each, rehydrated, and then gently rinsed using distilled water for 5 minutes. Antigen retrieval was done by steaming slides in 0.01 M sodium citrate buffer at pH 6.0 and temperature for 20 minutes. The slides were cooled and rinsed in Tris buffer solution (TBS) for 1 minute. Peroxidase block was then added for 10 minutes to all slides. Slides were then rinsed carefully in Tris buffer for 3 minutes. Two drops of rabbit monoclonal Anti-Wilms tumor protein antibody [(CAN-R9) IHC-56-2] ab89901 at a dilution of 1:300 and two drops of a rabbit monoclonal Anti-p53 antibody [E26] ab32389 at a dilution of 1:100 was added, respectively, to the slides and incubated for 1 hour at room temperature then carefully rinsed in Tris buffer 3 times as above. One to two drops of secondary antibody “horse radish peroxidase” DAKO HRP anti-rabbit Lot 11478723, manufactured by Dako, were added to the tissue sections stained for WT1 and p53, respectively, then incubated for 30 minutes at room temperature. Slides were again rinsed in Tris buffer as above. 3,3'-diaminobenzidine tetrahydrochloride chromogen was added to the tissue and incubated for 5–10 minutes. Counterstaining was done with hematoxylin, mounted and interpreted under a light microscope.

### Evaluation of Immunoreactivity

Interpretation of p53 was based on the protocol by Lahoti et al.<sup>11</sup> A case was considered positive if it had more than 5% of cells with nuclear staining, while those with less than 5% of cells with nuclear staining were considered negative.<sup>11</sup> Interpretation of WT1 was based on a protocol by Goyal et al, and a tumor with <10% of cells was considered negative, while those with >10% cells staining were considered positive.<sup>12</sup>



## Data Collection and Analysis

Details for all retrieved tissue blocks were obtained from the histopathology register and request forms; these were each given a unique identification number. Data collected included age in years, gender which was recorded as either male or female, histologic features, necrosis, WT1 immunostaining status, p53 immunostaining status, and histologic features. Raw data was entered in a password-protected Excel spreadsheet 2016. The dataset was imported into STATA software version 17 for cleaning and analysis. Age was described using median, and interquartile range. The histological features of WT were described using proportions. The expression of WT1 and p53 was described as proportions with a corresponding 95% confidence interval. The associations were determined using the chi-square test for independence. The association between WT1 and histologic features, p53, and histologic features was considered statistically significant if the p-value is  $<0.05$ .

## Ethical Considerations

The study obtained ethical approval from the Research Ethics Committee (REC) of Mbarara University of Science and Technology under number MUST-2022-736, which provided a waiver participant consent. Administrative clearance from the pathology department and Mbarara Regional Referral Hospital was also obtained. Caretakers and parents of children whose samples were used provided consent to have their samples stored in the histopathology for at least 10 years and any study that obtains ethical approval can use them. This was the basis for obtaining consent waiver for this study. There was therefore no further consenting needed for this study. The study respected all principles of medical ethics as prescribed in declaration of Helsinki.

## Results

### Baseline Characteristics of the Children Recruited

Table 1 shows the demographic characteristics of the children whose blocks were recruited. The median age of the children was 3.5 years, interquartile range was 2–6 years. Fifty-nine percent (59%) of the cases were below 4 years. There was almost an equal number of males and females accounting for 51% and 49%, respectively. Seventy-five percent (75%) of the specimens were nephrectomies.

**Table 1** Baseline Characteristics of the Children Whose Specimens Were Recruited

Variable	n (%)	95% CI*
Age		
<4 years	50 (58.82%)	47.96–68.89
>4 years	35 (41.18%)	31.11–52.04
Sex		
Male	43 (51%)	39.94–61.18
Female	42 (49%)	38.82–60.06
Nature of specimen		
Nephrectomy	64 (75%)	64.89–83.40
Trucut	21 (25%)	16.60–35.11
Necrosis		
Absent	54 (64%)	52.67–73.17
Present	31 (36%)	26.83–47.33

**Note:** \*Confidence interval.

**Table 2** Describing the Histologic Features of Wilms Tumor at MRRH

Histologic feature	n (%)	95% CI*
Epithelial predominant	18(21.18)	13.67–31.29
Blastemal predominant	17(20.0)	12.72–30.00
Stromal predominant	20(23.53)	15.61–33.84
Mixed type	30(35.29)	25.78–46.14
Anaplasia		
Present	5(5.88)	2.44–13.52
Absent	80(94.12)	86.48–97.56

Note: \*Confidence interval.

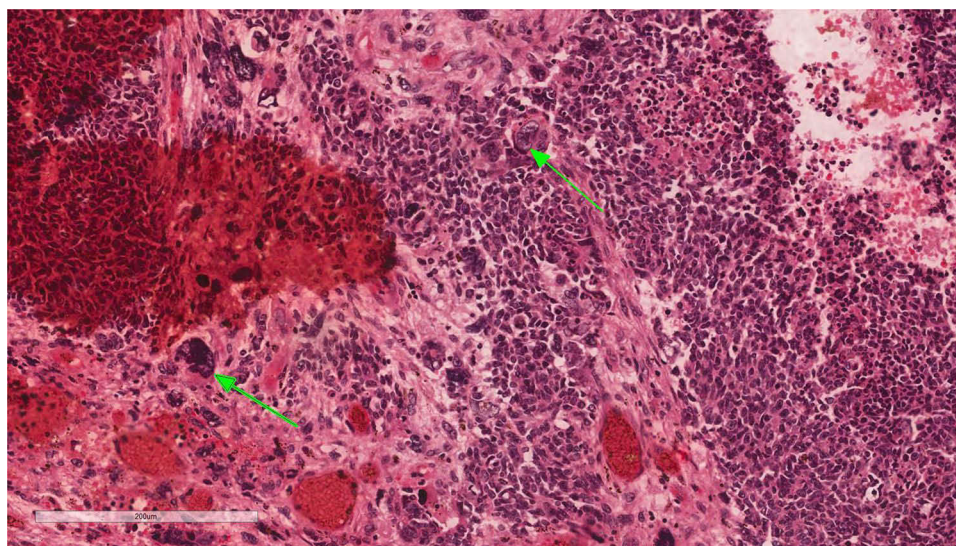
## Evaluation of Histologic Features and Expression of TP53 and WT1

The mixed type histology was the commonest histological feature accounting for 35.29% (95% CI 25.77–46.14) (Table 2). Anaplasia was present in 5.88% (2.44–13.52 95% CI) of specimens (Figure 1). The prevalence of WT1 expression (Figure 2) was 41.0% (95% 31.11–52.04), while that of p53 (Figure 3) was 13.0% (95% CI 7.25–22.04), respectively, as shown in Figures 4A and 5A. Fifty-nine percent of the cases did not express WT1 (Figure 4B), while 87% of the case did not express p53 (Figure 5B). Necrosis was present in 36% of the specimens recruited in this study.

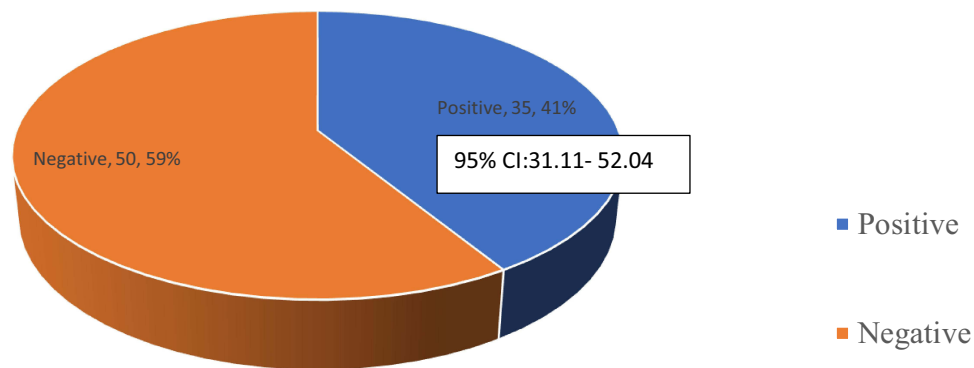
The relationship between histologic features and WT1 was not statistically significant Fisher's exact p-value of 0.459. However, 50% of specimens with mixed-type histology expressed WT1. The expression of TP53 was higher in stromal predominant at 20% (Table 3). However, there was no statistical difference in the expression of TP53 in all groups with a Fisher's exact p-value of 0.461. p53 was expressed in 20% of specimens with anaplasia on H&E, and 12.5% of those that did not have anaplasia on H&E; however, the difference was not statistically significant with Fisher's exact p-value of 0.509 (Table 4).

## Discussion

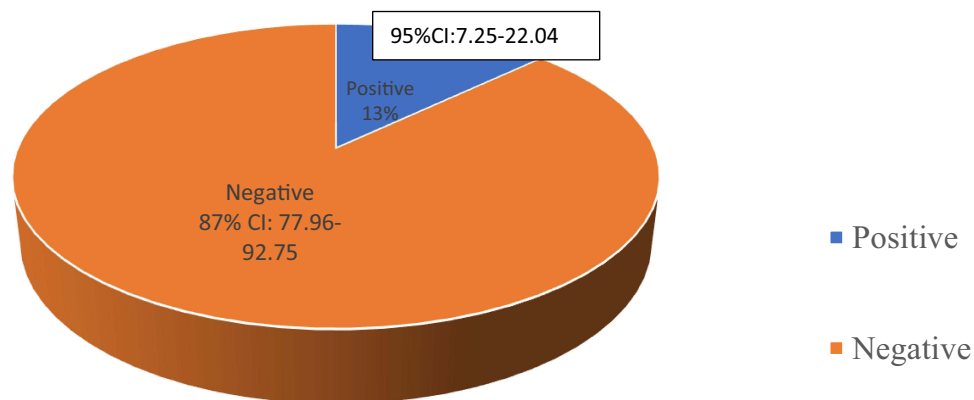
The study was carried out to describe WT histologic features and their association with the expression of p53, and WT1 in archived tissue blocks of children with a confirmed diagnosis of WT at a Public Regional Referral Hospital in South



**Figure 1** Showing a tumor with anaplasia X200. The green arrows show large cells with irregular nuclear membranes, hyperchromasia, and mitoses.



**Figure 2** A pie chart showing the prevalence of WT1.

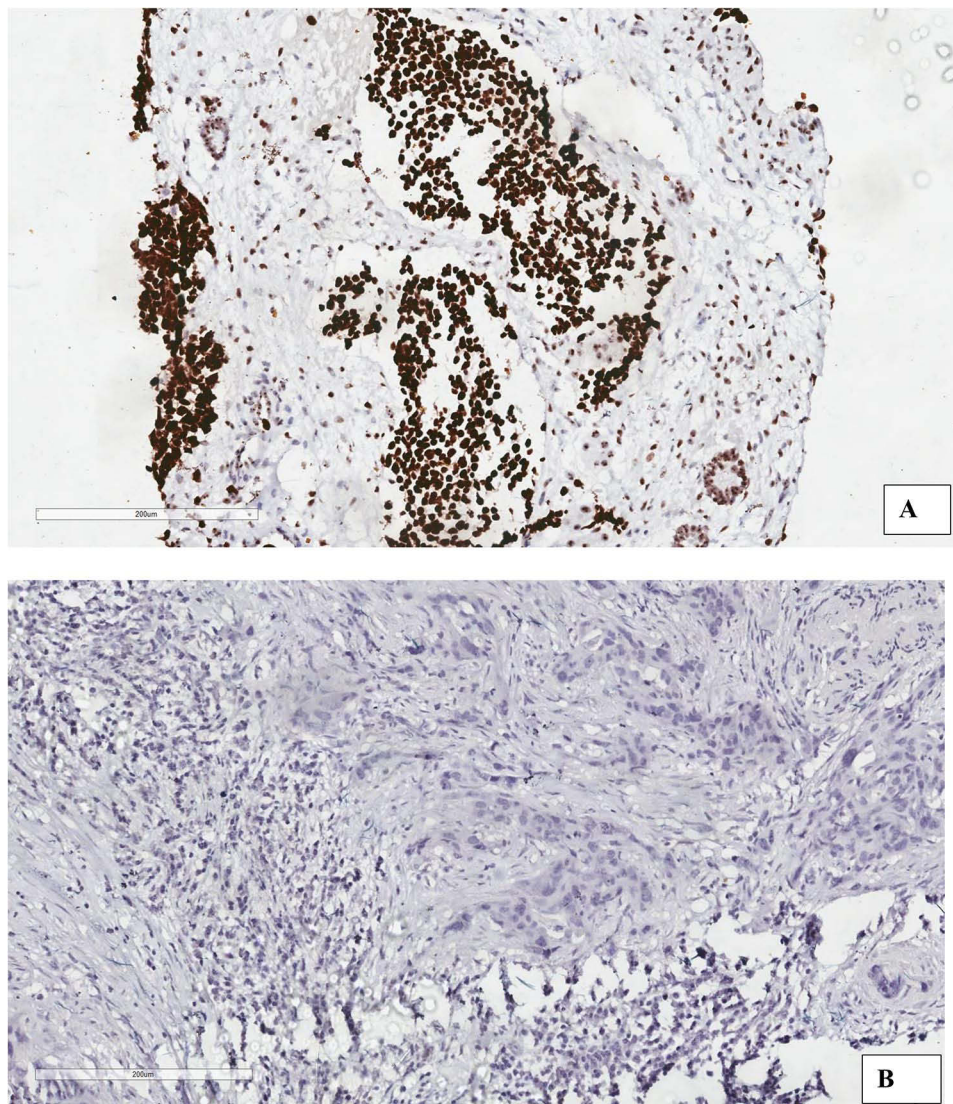


**Figure 3** A pie chart showing the prevalence of p53.

Western Uganda. The main findings in this study include mixed type being the commonest histologic feature of WT, high expression of WT1, low expression of p53, and low prevalence of anaplasia.

The mixed type histology being the commonest histological feature of WT at 35.29% 95% CI: 25.77–46.14 is comparative to findings from the United Kingdom Children's Cancer study group Wilms trial 3, Weirich et al, and Zuppan et al which had 25%, 29.4%, and 33.3% of specimens as mixed type histology, respectively.<sup>5,13,14</sup> This can be explained by the fact that in all these studies just like this one, the same grading system was used. The findings, however, are different from those reported elsewhere by Darwish 97.1% triphasic predominant in Egypt, 46.7% blastemal predominant in Nigeria, 49.2% blastemal predominant in Egypt, 81.9% triphasic predominant in Uganda, and 43% blastemal predominant in Uganda.<sup>15–19</sup> The difference can be explained by the variations in interpretations of the SIOP 2001 protocol<sup>10</sup> used in the classification of tumors that have received pre-operative chemotherapy, whereas the protocol does not recognize the term triphasic, some of the studies reported such a category that would otherwise be put under mixed type. The mixed type in this study is lower than 53.3% found in China among patients who had received chemotherapy.<sup>20</sup> This can be explained by differences in methodology. Huang et al recruited only tumors without anaplasia following the COG protocol. Both trucut and nephrectomy specimens were obtained before chemotherapy. This is different from our study where most of the specimens recruited had received pre-operative chemotherapy which could have altered the histologic features.

The low prevalence (5.88%) of anaplasia is similar to findings by Dome et al, Morgan et al, and Murphy of 7.2% and 13%, respectively.<sup>6,18,21</sup> The similarity can be explained by the fact that all these were laboratory studies and involved a review of tissue blocks similar to what we did. However, this is lower than the 63% and 24.39% reported by Okello et al and Ekuk et al, respectively.<sup>19,22</sup> This discrepancy can be explained by the fact that these studies were reviewing

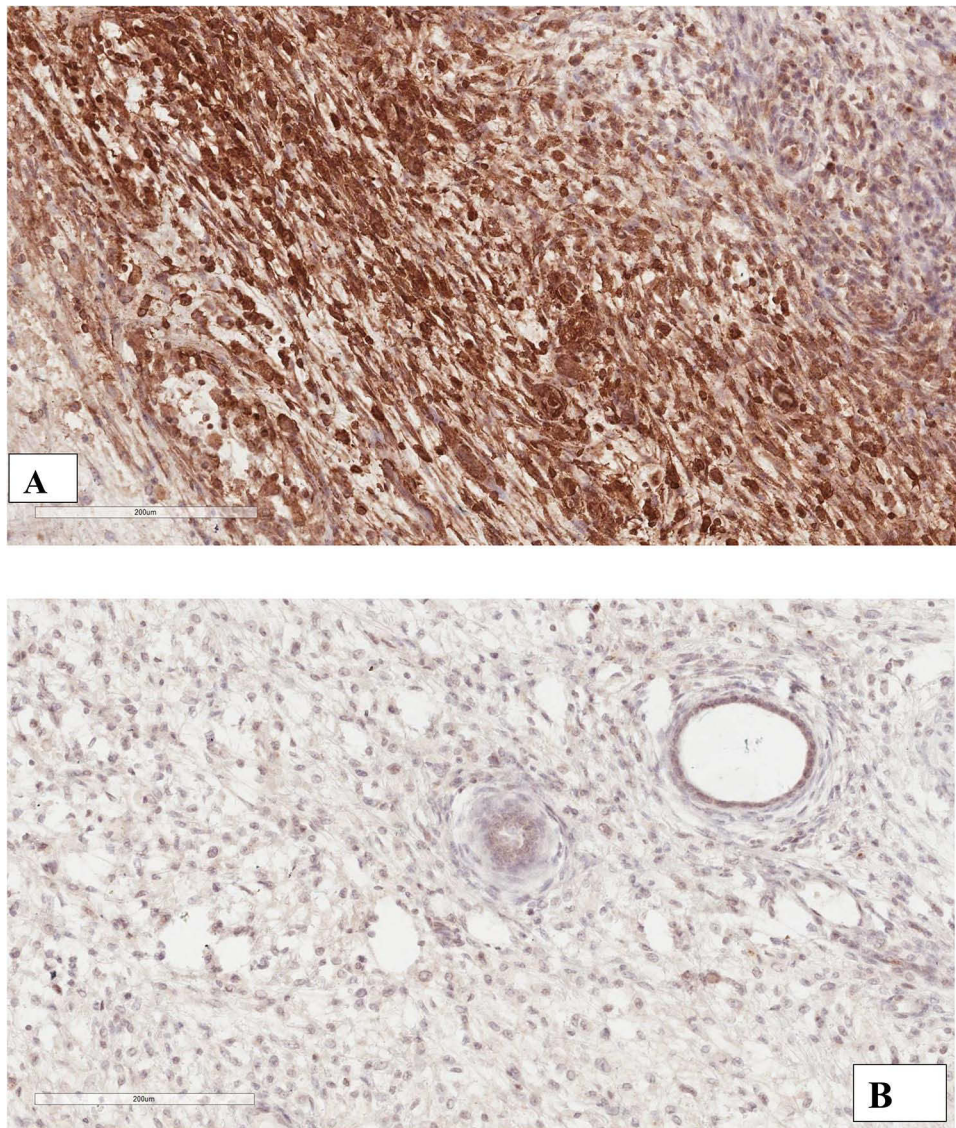


**Figure 4** (A) Shows a tumor positive for WT1, and (B) Shows a tumor negative for WT1. All images were taken at x200.

patient charts on pediatric oncology and did not review histology slides. There is a possibility that some cases, especially those which were diagnosed outside our laboratory, were misdiagnosed.

The low expression of p53 (13%) is similar to findings from India of 9.7% and 16.0%, 16.7% from Nigeria studies, and 8.4% in Uganda by Morgan.<sup>16,18,23,24</sup> All these studies involved the review of histology slides similar to what we did. The similarity between Nigeria and Uganda studies can also be explained by the similarity in participants' clinical characteristics. The expression of p53, however, was lower than 60.3%, and 56% from Egypt and 40% from Kenya.<sup>15,17,21</sup> A study by Salama recruited only nephrectomy specimens and would only include a specimen with at least 4 representative slides, as opposed to our study where even trucut biopsies were recruited which could have affected tumor topography. A study by Murphy received specimens from multiple sites which could have affected tissue processing. A study by Darwish used a different antibody clone from what we used of Genemed Biotechnologies, Mouse monoclonal anti-p53, clone BP-53-12 while in our study we used recombinant anti-p53[E26] rabbit monoclonal antibody from Abcam.

The expression of WT1 is lower than 66.7% reported in the study done at Osaka University in Japan and 100% by Murphy.<sup>21,25</sup> The difference can be attributed to the different clone 6F-H2 anti-rabbit antibody used as opposed to our CAN-R9 IHC-56-2, while a study by Murphy recruited only blocks for 21 patients.



**Figure 5** (A) Shows a tumor positive for p53, and (B) Shows a tumor negative for p53 all images were taken at x200.

The findings of the association between p53 and histologic features are similar to studies in India and Belgium.<sup>23,24</sup> The presence of p53 in non-anaplastic tumors is similar to what was found by Govender et al.<sup>26</sup> The findings are, however, different from the findings by Salama et al, Atanda et al, and Darwish et al who found a significant relationship between histology component and TP53. This could also be attributed to the dominant mixed-type histology in our study

**Table 3** Describing the Relationship Between Histologic Features and WT1

Variable	Negative n (%)	Positive n (%)	Total	Fisher's Exact p-value
WT1				
Epithelial predominant	12 (66.67)	6 (33.33)	18 (100)	0.459
Blastemal predominant	9 (52.94)	8 (47.06)	17 (100)	
Stromal predominant	14 (70)	6 (30)	20 (100)	
Mixed type	15 (50)	15 (50)	30 (100)	

**Table 4** Showing association between histologic features and p53

Histologic Features	Negative n (%)	Positive n (%)	Total	Fisher's Exact p-value
p53				
Epithelial predominant	16 (88.89)	2 (11.11)	18 (100)	0.461
Blastemal predominant	14 (82.35)	3 (17.65)	17 (100)	
Stromal predominant	16 (80)	4 (20)	20 (100)	
Mixed type	28 (93.33)	2 (6.67)	30 (100)	
Anaplasia	p53			
Absent	70 (87.50)	10 (12.50)	80 (100)	0.509
Present	4 (80)	1 (20)s	5 (100)	

compared to the blastemal component in these studies where p53 is mostly expressed.<sup>15–17</sup> The number of anaplastic tumors positive for p53 was lower than 76.2% reported in a study by Hill<sup>27</sup> which can be attributed to the large sample size of tumors known to have anaplasia recruited in this study. The difference can be explained by the fact that Hill et al recruited nephrectomy and trucut specimens that had not received preoperative chemotherapy as opposed to our study where most samples were after preoperative chemotherapy. The 20% positivity of TP53 in anaplastic tumors is also lower than the 83.3% reported by Morgan at Makerere histopathology laboratory.<sup>18</sup> The lack of statistically significant association between p53 and histologic features can be explained by the fact that most cases had mixed-type histology which virtually does not express p53.<sup>28</sup>

The strength of the study is that this is the known laboratory-based study describing histology features of Wilms tumor and expression of p53 and WT1 in South Western Uganda.

The weakness is that this is a single-site study whose findings may not be generalizable to other sites. There is therefore need to carry out multisite studies to obtain findings that can be generalized. The study reports a low expression of p53 in anaplastic cases which may not be generalized to other sites. There is therefore need for another study using the ready to use antibody that have been used in other studies that reported a high expression of p53.

In conclusion, mixed-type histology is the most common histologic feature of WT in South Western Uganda with high expression of WT1 and low expression of p53. The low expression of p53 correlates well with the low prevalence of anaplasia detected on H&E. This implies that these markers can be used routinely in confirmation of WT diagnosis as well as ruling out anaplasia which will in turn reduce unnecessary exposure to high doses of post-operative chemotherapy in children with Wilms tumor. We recommend standardized reporting of Wilms tumor samples based on the SIOP protocol to provide clear guidance to clinicians on the next course of action in terms of postoperative chemotherapy regimens. There is a need to routinely use WT1 and p53 in Wilms tumor cases in South Western Uganda especially those where neoadjuvant chemotherapy has been administered and anaplasia is suspected on hematoxylin and eosin-stained sections.

## Abbreviations

WT1, Wilms tumor gene one; UCI, Uganda Cancer Institute; MRRH, Mbarara Regional Referral Hospital; WT, Wilms tumor; COG, Children Oncology Group

## Data Sharing Statement

The dataset used and analyzed in this study is available on request from the corresponding author.

## Acknowledgments

We acknowledge the histopathology laboratory staff who ensured that all laboratory processes are completed on time.

## Author Contributions

All authors contributed to data analysis, drafting or revising the article, have agreed on the journal to which the article will be submitted, gave final approval of the version to be published, and agree to be accountable for all aspects of the work.

## Funding

There is no funding to report.

## Disclosure

The authors report no conflicts of interest in this work.

## References

1. American cancer society cancer facts and figures. Available from: <https://www.cancer.org/research/cancer-facts-statistics/all-cancer-facts-figures/cancer-facts-figures-2022.html>. Accessed November 18.
2. Diakit  F, Togo P, Doumbia A, et al. Prevalence and Prognosis of relapse of nephroblastoma at the pediatric oncology unit of Bamako. *Open J Pediatr*. 2019;9(04):317. doi:10.4236/ojped.2019.94031
3. Stefan DC. Patterns of distribution of childhood cancer in Africa. *J Trop Pediatr*. 2015;61(3):165–173. doi:10.1093/tropej/fmv005
4. Mbarara Regional Referral Hospital Pediatric oncology, Soid tumors. Mbarara regional referral hospital mbarara regional referral hospital; 2021.
5. Vujani  GM, D’Hooghe E, Popov SD, Sebire NJ, Kelsey A. The effect of preoperative chemotherapy on histological subtyping and staging of Wilms tumors: the United Kingdom Children’s Cancer Study Group (UKCCSG) Wilms tumor trial 3 (UKW3) experience. *Pediatr Blood Cancer*. 2019;66(3):e27549. doi:10.1002/pbc.27549
6. Dome JS, Cotton CA, Perlman EJ, et al. Treatment of anaplastic histology Wilms’ tumor: results from the fifth National Wilms’ Tumor Study. *J Clin Oncol*. 2006;24(15):2352–2358. doi:10.1200/JCO.2005.04.7852
7. Kumar V, Abbas AK, Fausto N, Aster JC. *Robbins and Cotran Pathologic Basis of Disease, Professional Edition e-Book*. Elsevier health sciences; 2014.
8. Daniel WW, Cross CL. *Biostatistics: A Foundation for Analysis in the Health Sciences*. Wiley; 2018.
9. Angucia B, Nabwana M, Asasira J, Mulumba Y, Mutyaba I, Jackson O. Spectrum of primary cancer diagnoses among patients at Uganda Cancer Institute in 2015 and 2016. *Am Soc Clin Oncol*. 2018;2018:1.
10. Vujani  GM, Sandstedt B. The pathology of Wilms’ tumour (nephroblastoma): the International Society of Paediatric Oncology approach. *J Clin Pathol*. 2010;63(2):102–109. doi:10.1136/jcp.2009.064600
11. Lahoti C, Thorner P, Malkin D, Yeger H. Immunohistochemical detection of p53 in Wilms’ tumors correlates with unfavorable outcome. *Am J Pathol*. 1996;148(5):1577.
12. Goyal S, Mishra K, Sarkar U, Sharma S, Kumari A. Diagnostic utility of Wilms’ tumour-1 protein (WT-1) immunostaining in paediatric renal tumours. *Indian J Med Res*. 2016;143(Suppl 1):S59. doi:10.31254/jmr.2016.2304
13. Weirich A, Leuschner I, Harms D, et al. Clinical impact of histologic subtypes in localized non-anaplastic nephroblastoma treated according to the trial and study SIOP-9/GPOH. *Ann Oncol*. 2001;12(3):311–319. doi:10.1023/a:1011167924230
14. Zuppan CW, Weeks DA, Weeks DA, et al. The effect of preoperative therapy on the histologic features of Wilms’ tumor. An analysis of cases from the Third National Wilms’ Tumor Study. *Cancer*. 1991;68(2):385–394. doi:10.1002/1097-0142(19910715)68:2<385::aid-cnrc2820680229>3.0.co;2-t
15. Darwish A, Alemam D, Sheta H. Role of expression of p53 and Ki67 in the progression of Wilms tumor: correlation with patients’ survival. *Int J Cancer Biomed Res*. 2021;5(2):99–110.
16. Atanda AT, Anyanwu L-JC, Atanda OJ, Mohammad AM, Abdullahi LB, Farinyaro AU. Wilms’ tumour: determinants of prognosis in an African setting. *Afr J Paediatr Surg*. 2015;12(3):171. doi:10.4103/0189-6725.170185
17. Salama A, Kamel A. Evaluation of nuclear unrest and p53 immunostaining in Wilms’ tumor. *J Egypt Natl Canc Inst*. 2011;23(1):31–39.
18. Morgan ED, Yahaya JJ, Ngaiza AI, et al. Immunohistochemical expression of P53 protein in nephroblastoma: a predictor of unfavorable prognosis. *J Egypt Natl Canc Inst*. 2023;35(1):23.
19. Okello I, Tibenderana R, Lubega A, Tuhairwe E, Situma M. Wilms tumour among children attending Mbarara Regional Referral Hospital: clinico-pathological characteristics and outcome at the end of treatment. *East Central Afr J Surg*. 2019;24(1):28–34.
20. Huang J, Zhang Y, Zhen Z, et al. The prognosis of prechemotherapy blastemal predominant histology subtype in Wilms tumor: a retrospective study in China. *Pediatr Blood Cancer*. 2020;67(11):e28567. doi:10.1002/pbc.28567
21. Murphy AJ, Axt JR, de Caeestecker C, et al. Molecular characterization of Wilms’ tumor from a resource-constrained region of sub-Saharan Africa. *Int J Cancer*. 2012;131(6):E983–E994. doi:10.1002/ijc.27544
22. Eku E, Odongo CN, Tibajjuka L, et al. One year overall survival of Wilms tumor cases and its predictors, among children diagnosed at a teaching hospital in South Western Uganda: a retrospective cohort study. *BMC Cancer*. 2023;23(1):1–10.
23. Krishna O, Kayla G, Abdul Aleem M, et al. Immunohistochemical expression of Ki67 and p53 in Wilms tumor and its relationship with tumor histology and stage at presentation. *Pathol Res Int*. 2016;2016. doi:10.1155/2016/6123951
24. Das RN, Chatterjee U, Sinha SK, et al. Study of histopathological features and proliferation markers in cases of Wilms’ tumor. *Indian J Med Paediatr Oncol*. 2012;33(02):102–106.
25. Oue T, Uehara S, Yamanaka H, et al. Expression of Wilms tumor 1 gene in a variety of pediatric tumors. *J Pediatr Surg*. 2011;46(12):2233–2238. doi:10.1016/j.jpedsurg.2011.09.004

26. Govender D, Harilal P, Hadley G, et al. p53 protein expression in nephroblastomas: a predictor of poor prognosis. *Br J Cancer*. 1998;77(2):314–318. doi:10.1038/bjc.1998.48
27. Hill DA, Shear TD, Liu T, et al. Clinical and biologic significance of nuclear unrest in Wilms tumor. *Cancer*. 2003;97(9):2318–2326. doi:10.1002/cncr.11325
28. Dome JS, Perlman EJ, Graf N. Risk stratification for Wilms tumor: current approach and future directions. *Am Soc Clin Oncol Educ Book*. 2014;34(1):215–223.

Cancer Management and Research

Dovepress

### Publish your work in this journal

Cancer Management and Research is an international, peer-reviewed open access journal focusing on cancer research and the optimal use of preventative and integrated treatment interventions to achieve improved outcomes, enhanced survival and quality of life for the cancer patient. The manuscript management system is completely online and includes a very quick and fair peer-review system, which is all easy to use. Visit <http://www.dovepress.com/testimonials.php> to read real quotes from published authors.

Submit your manuscript here: <https://www.dovepress.com/cancer-management-and-research-journal>