



## Case report

## Endometriosis arising in a cesarean section scar: A case report

Robert Masereka<sup>a,b</sup>, Sonye Magugu Kiyaka<sup>a</sup>, Franck Katembo Sikakulya<sup>a,c,\*</sup><sup>a</sup> Faculty of Clinical Medicine and Dentistry, Department of Surgery, Kampala International University Western Campus, Ishaka, Bushenyi, Uganda<sup>b</sup> Department of Surgery, Jinja Regional Referral Hospital, Jinja, Uganda<sup>c</sup> Faculty of Medicine, Université Catholique du Graben, Butembo, Democratic Republic of the Congo

## ARTICLE INFO

## Keywords:

Endometriosis  
Abdominal wall scar  
Cesarean

## ABSTRACT

**Introduction and importance:** Scar endometriosis is an uncommon variant of extra pelvic endometriosis, which develops at the scar site of previous abdominopelvic surgery and is seen in women during their reproductive period.

**Case presentation:** We report a 38-year-old female who presented with a nine-months history of a painful ulcerative mass that developed on a cesarean section scar. The mass was removed by a wide excision and confirmed by histology to be endometriosis.

**Clinical discussion:** Wide surgical resection of ectopic endometriosis is the treatment of choice. It is usually curative and ensures the confirmation of the diagnosis.

**Conclusion:** Cesarean section scar endometriosis can undergo malignant transformation. This case highlights the need for early detection and treatment.

## 1. Introduction

Endometriosis was first described by Karl Von Rokitansky in 1860, who defined it as the presence and development of functional endometrial tissue in locations other than the uterine lining [1]. Major sites for extra-pelvic endometriosis include the lungs, pleura, kidneys, bladder, omentum, bowel, lymph nodes, and abdominal wall [2].

The incidence of endometriosis developing in a surgical scar after cesarean section is reported to be 0.03–0.45%, and it may cause long-term discomfort and cyclic lower abdominal pain [3–4].

Variability in clinical presentation and lack of knowledge about the disease may lead to misdiagnosis and delay in management, which have negative and possibly life-threatening consequences for the patient's wellbeing and quality of life with a risk of malignancy transformation [5]. This case report has been reported in line with the SCARE 2020 criteria [6].

## 2. Case presentation

A 38-year-old woman who presented with a markedly tender ulcerated mass (4 cm in widest dimension) in the upper 1/3 of a sub-umbilical midline cesarean section scar [Fig. 1]. On examination the patient was in

pain and unable to stand upright. An abdominal ultrasound scan showed normal intra-abdominal findings.

The swelling was first noticed by the patient 9 months ago and had become progressively larger and more painful. Four months after it first appeared the patient noticed that the swelling would ulcerate, bleed and become painful for three days or so every month during her menstrual period.

The patient had delivered three children between 11 and 16 years prior to presentation, the first was delivered by cesarean section, and two subsequent children were by normal vaginal delivery. For 7 years prior to presentation the patient was on three monthly injections of Depo-Provera for contraception.

The history and examination made endometriosis of the cesarean section scar a likely diagnosis, which was confirmed by histology after full thickness wide excision of the mass [Figs. 2 and 3]. The patient was discharged uneventfully from the hospital on the 2nd postoperative day. On follow-up, 3 months later, she had no complaints and was fully recovered [Fig. 4].

## 3. Discussion

Although endometriosis development in surgical scars is most often seen after cesarean section [7], it can develop after a variety of other

\* Corresponding author at: Faculty of Clinical Medicine and Dentistry, Department of Surgery, Kampala International University Western Campus, Ishaka, Bushenyi, Uganda.

E-mail address: [francksikakulya@gmail.com](mailto:francksikakulya@gmail.com) (F.K. Sikakulya).

<https://doi.org/10.1016/j.ijscr.2022.106862>

Received 25 December 2021; Received in revised form 17 February 2022; Accepted 22 February 2022

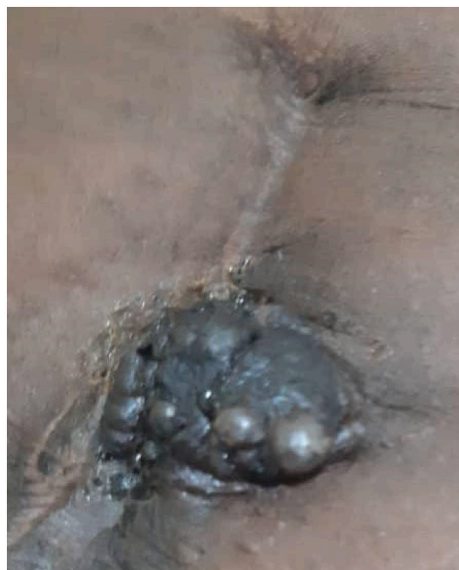Available online 25 February 2022

2210-2612/© 2022 The Authors. Published by Elsevier Ltd on behalf of IJS Publishing Group Ltd. This is an open access article under the CC BY-NC-ND license

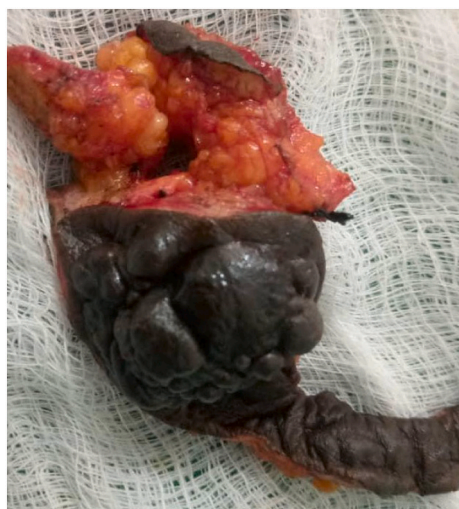(<http://creativecommons.org/licenses/by-nc-nd/4.0/>).

**Abbreviations**

|       |                                |
|-------|--------------------------------|
| C/S   | cesarean section               |
| Ca125 | cancer antigen 125             |
| CSE   | cesarean section Endometriosis |
| CT    | computed tomography scan       |
| MRI   | magnetic resonance imaging     |
| SUMS  | sub-umbilical midline scar     |
| SVD   | spontaneous vaginal delivery   |



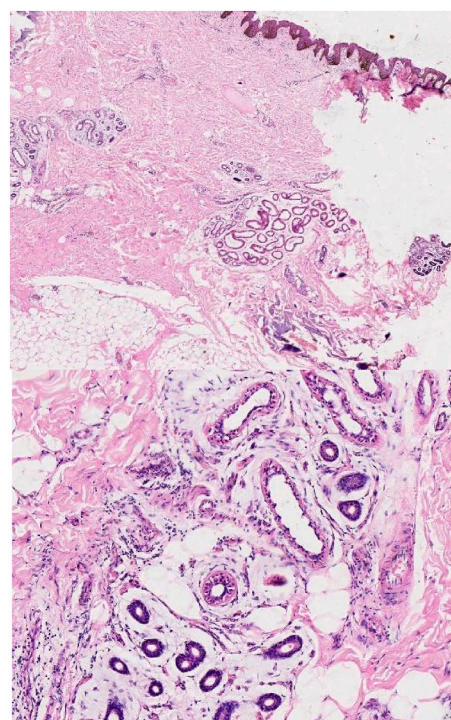
**Fig. 1.** Photography of the cesarian section scar showing a bourgeoning mass.



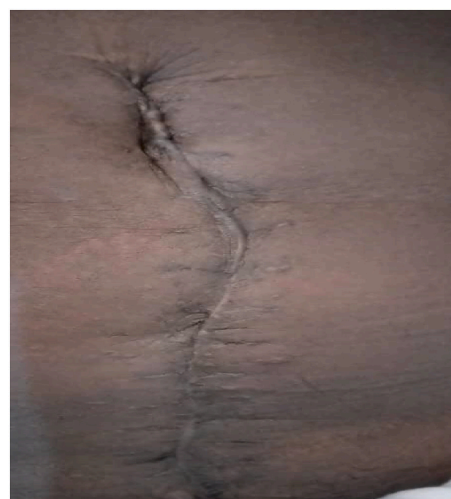**Fig. 2.** Photography of intra-operative findings showing the cesarian section scar's mass after full resection.

procedures, such as hysterectomies, cystectomies, tubal ligations, amniocentesis [8], episiotomy [9], appendectomies, umbilical hernioplasty, and laparoscopic trocar tracts [10–11].

Implantation of endometrial tissue into a surgical incision has been



**Fig. 3.** Histology pictures showing benign skin with underlying stroma being infiltrated by island composed of benign endometrial glands and stroma associated with extracellular hemorrhage and chronic inflammation suggestive of endometriosis.



**Fig. 4.** Photography of the scar 3 months post-surgery.

proposed as an explanation of the condition's pathophysiology [12]. It is thought that during a cesarean delivery endometrial tissue is inoculated into the incision. With an appropriate supply of nutrients and hormonal stimuli, these endometrial cells survive and proliferate if there are sufficient nutrients and the appropriate hormonal environment [7].

The differential diagnosis of abdominal wall endometriosis includes abscess, lipoma, hematoma, granuloma, neuroma, sebaceous cyst, incisional hernia, lymphoma, sarcoma, etc. [13]. The clinical presentation may be variable and, as in our patient, may not occur until years after surgery. If present, an important clinical clue is a slowly growing painful palpable mass in the area of an old scar, which increases in size and becomes more painful during menstruation. Although pain is the predominant symptom and occurs in almost all cases, unfortunately

almost half of patients do not exhibit the condition's characteristic periodicity in pain [14]. Histology examination remains the diagnostic test of choice [15].

Administration of hormonal preparations offer only temporary relief of symptoms [16]. Wide surgical resection of ectopic endometriosis is the treatment of choice, even for repeated recurrent lesions. It is usually curative and ensures the confirmation of diagnosis. The prognosis of ectopic endometriosis is good with an immediate relief of the symptoms after surgery.

Unfortunately, scar associated endometriosis can undergo malignant transformation [5]. Although CT scan and MRI are better able to determine the extent of infiltration of adjacent tissues by ectopic endometriosis [17], ultrasound scan was the only investigation available to this patient. Our patient's ultrasound examination was normal, and ultrasound is a practical and affordable method of patient follow-up in a low resource setting [18]. In addition to early detection, serological markers can be used for postoperative monitoring to detect both recurrence and malignant transformation. Although cancer antigen 125 (Ca125) over 1000 UI/ml has a specificity of 83–93% for invasive disease [14], its sensitivity has been reported to range from 24 to 94% [19]. Therefore, this test may not be a reliable screening test.

#### 4. Conclusion

Endometriosis arising in a cesarean section scar is an uncommon form of extra pelvic endometriosis. Although there is a wide differential diagnosis for swellings of the abdominal wall, it should be suspected in any female patient with a lesion in surgical scar, which becomes more painful and swollen during her menstrual period. Unfortunately, not all patients have this presentation. There is not much to do in preventing occurrence of this condition in those that are predisposed however the role of the surgeon is a high index of suspicion, early diagnosis and surgical intervention to limit the morbidity and/or prevention of malignant transformation.

#### Consent for publication

Written informed consent was obtained from the patient for publication of this case report and accompanying images. A copy of the written consent is available for review by the Editor-in-Chief of this journal on request.

#### Funding

The author FKS was supported by Safe Surgery DRC (SS-DRC). The funder had no role in study design, data collection and analysis, decision to publish, or preparation of the manuscript.

#### Availability of data and materials

All data generated or analyzed during this study are included in this published article.

#### Ethics approval and consent to participate

Not applicable.

#### Research registration

Not applicable.

#### Guarantor

Franck Katembo Sikakulya

#### Provenance and peer review

Not commissioned, externally peer-reviewed.

#### CRedit authorship contribution statement

MR managed the patient and SMK and FKS wrote the first draft. All authors read and approved the final manuscript.

#### Declaration of competing interest

The authors declare no conflicts of interest.

#### Acknowledgements

Authors are grateful to Dr. John Kellett for proofreading this case report.

#### References

- [1] American College of Obstetricians and Gynecologists, Practice bulletin no. 114: management of endometriosis, *Obstet. Gynecol.* 116 (1) (2010) 223–236.
- [2] H. Bektaş, Y. Bilsel, Y.S. Sar, Abdominal wall endometrioma; a 10-year experience and brief review of the literature, *J. Surg. Res.* 164 (1) (2010) e77–e81.
- [3] L. Taburiaux, N. Pluchino, P. Petignat, J.M. Wenger, Endometriosis-associated abdominal wall cancer, *Int. J. Gynecol. Cancer* 25 (9) (2015 Nov) 1633–1638.
- [4] Y. Chang, E.M. Tsai, C.Y. Long, Y.H. Chen, N. Kay, Abdominal wall endometriomas, *J. Reprod. Med.* 54 (3) (2009) 155–159.
- [5] D. Oxholm, U.B. Knudsen, N. Kryger-Baggesen, P. Ravn, Postmenopausal endometriosis, *Acta Obstet. Gynecol. Scand.* 86 (2007) 1158.
- [6] R.A. Agha, T. Franchi, C. Sohrabi, G. Mathew, for the SCARE Group, The SCARE 2020 guideline: updating consensus Surgical Case Report (SCARE) guidelines, *Int. J. Surg.* 84 (2020) 226–230.
- [7] N.S. Nominato, L.F. Prates, I. Lauer, J. Morais, L. Maia, S. Geber, Cesarean section greatly increases risk of scar endometriosis, *Eur. J. Obstet. Gynecol. Reprod. Biol.* 152 (1) (2010) 83–85.
- [8] M. Mistrangelo, N. Gilbo, P. Cassoni, et al., Surgical scar endometriosis, *Surg. Today* 44 (4) (2014) 767–772.
- [9] J.C. Márquez, J. Márquez, J.A. Arratzoa, G. Pérez, A. Espinoza, Endometriosis extrapelviana de ubicación perineal, *Rev. Chil. Obstet. Ginecol.* 60 (1) (1995) 1–4.
- [10] J.D. Horton, K.J. DeZee, E.P. Ahnfeldt, M. Wagner, Abdominal wall endometriosis: a surgeon's perspective and review of 445 cases, *Am. J. Surg.* 196 (2) (2008) 207–212.
- [11] A. Emre, S. Akbulut, M. Yilmaz, Z. Bozdog, Laparoscopic trocar port site endometriosis: a case report and brief literature review, *Int. Surg.* 97 (2) (2012) 135–139.
- [12] J.D. Horton, K.J. Dezee, E.P. Ahnfeldt, M. Wagner, Abdominal wall endometriosis: a surgeon's perspective and review of 445 cases, *Am. J. Surg.* 196 (2) (2008) 207–212.
- [13] G. Pachori, R. Sharma, R.K. Sunaria, T. Bayla, Scar endometriosis: diagnosis by fine needle aspiration, *J. Cytol.* 32 (2015) 65–67.
- [14] L. Ozel, J. Sagioglu, A. Unal, E. Unal, P. Gunes, et al., Abdominal wall endometriosis in the cesarean section surgical scar: a potential diagnostic pitfall, *J. Obstet. Gynaecol. Res.* 38 (2012) 526–530.
- [15] S. Dash, S. Panda, N. Rout, S. Samantaray, Role of fine needle aspiration cytology and cell block in diagnosis of scar endometriosis: a case report, *J. Cytol.* 32 (2015) 71–73.
- [16] C.C. Teng, H.M. Yang, K.F. Chen, C.J. Yang, L.S. Chen, et al., Abdominal wall endometriosis: an overlooked but possibly preventable complication, *Taiwan J. Obstet. Gynecol.* 47 (2008) 42–48.
- [17] A. Hassanin-Negila, S. Cardini, V. Ladam-Marcus, J.P. Palot, M.D. Diebold, Endometriomas of the abdominal wall: imaging findings, *J. Radiol.* 87 (2006) 1691–1695.
- [18] J. Brosens, D. Timmerman, A. Starzinski-Powitz, I. Brosens, Noninvasive diagnosis of endometriosis: the role of imaging and markers, *Obstet. Gynecol. Clin. N. Am.* 30 (2003) 95–114.
- [19] M.A. Bedaiwy, T. Falcone, Laboratory testing for endometriosis, *Clin. Chim. Acta* 340 (2004) 41–56.