



Case report

Gastroduodenal intussusception as a rare cause of pancreatitis in a young female Ugandan: A case report

Okello Michael^{a,b,*}, Kayondo Derick^b, Ocama Ponsiano^c^a Department of Anatomy, Makerere University College of Health Sciences, P.O. Box 7072, Kampala, Uganda^b Uganda Martyrs Hospital Lubaga, P.O. Box 14130, Kampala, Uganda^c Department of Medicine, Makerere University College of Health Sciences, P.O. Box 7072, Kampala, Uganda

ARTICLE INFO

Keywords:

Pancreatitis
Intussusception
Gastrectomy
GIST
Case report
Uganda

ABSTRACT

Introduction and importance: Gastroduodenal intussusceptions are rare and usually secondary to gastric lesions acting as the lead point. Gastrointestinal stromal tumors (GISTs) commonly occur in the stomach (40–60%). Other gastric tumors include; adenocarcinomas, leiomyomas, lymphomas among others. When gastric tumors act as lead points in gastroduodenal intussusception, pancreatitis may arise due to compression of the ampulla of Vater or pancreatic head. Gastroduodenal intussusception may mimic other inflammatory upper gastrointestinal conditions leading to delays in early diagnosis and timely intervention.

Case presentation: A twenty three year old female with gastroduodenal intussusception secondary to a gastric body GIST with associated pancreatitis. This gastroduodenal mass was initially diagnosed as a pancreatic head echo-complex mass by ultrasound. Confirmatory preoperative diagnosis was made after doing contrasted abdominal computed tomography (CT) scan and upper gastrointestinal endoscopy. Open gastric wedge resection was done. Patient had uneventful recovery and was discharged on the fifth postoperative day.

Clinical discussion: Gastroduodenal intussusceptions have non-specific clinical features that may lead to delays in making the correct diagnosis. CT scan is a good imaging modality for diagnosing this condition but access is limited in low resource settings. Resection of the organic cause after reducing the intussusception leads to resolution of the symptoms caused by the intussusception, the GIST and the resultant pancreatitis.

Conclusion: Gastroduodenal intussusception is rare and may present with nonspecific clinical features. Pancreatitis may arise due to the compression effects on the ampulla of Vater or pancreatic head. A high index of suspicion is key in making a timely diagnosis.

1. Introduction

Gastrointestinal stromal tumors (GISTs) are the most common mesenchymal tumors that arise from neoplastic transformation of interstitial cells of Cajal [1]. Close to 90% of GISTs are immunohistochemically positive for c-kit gene (CD117) and 70% for CD34 [2]. They account for 1–3% of all malignant gastrointestinal tumors and occur anywhere along the gastrointestinal tract most commonly in the stomach (40–60%) and the jejunum/ileum (25–30%). Other less common sites for GISTs include; the duodenum (5%), colon and rectum (5–15%), esophagus ($\leq 1\%$) and other various locations (5.5%) [1,3,4]. GISTs have a low rate of metastasis. The liver is the most common site of metastases. The general rate of metastasis to the liver is 9.19%, to the lungs is 0.76% and to the bones is 0.76% [5]. Intussusception is the

telescoping of the proximal segment of the gastrointestinal tract (intussusceptum) into an adjacent segment (intussusception). Adult intussusceptions are rare accounting for only 5% of all intussusceptions and the 90% of the adult intussusceptions are associated with an organic cause, 20–50% of the organic causes in adults may be malignant. The majority of intussusceptions in the pediatric population are idiopathic (90%) [6,7]. Gastroduodenal intussusception is even more rare accounting for <10% of all adult intussusceptions and not commonly associated with pancreatitis [8].

The chief surgeon of Lubaga Hospital operated on the patient presented in this case report. Lubaga Hospital is the second oldest hospital in Uganda and was founded by the Catholic Church missionaries in 1899. It currently has a bed capacity of 275.

This work has been reported in line with the SCARE 2020 criteria

* Corresponding author at: Department of Anatomy, Makerere University College of Health Sciences, P.O. Box 7072, Kampala, Uganda.

E-mail address: dr.okelloaleleu@gmail.com (O. Michael).

<https://doi.org/10.1016/j.ijscr.2021.106632>

Received 6 October 2021; Received in revised form 17 November 2021; Accepted 21 November 2021

Available online 25 November 2021

2210-2612/© 2021 The Authors. Published by Elsevier Ltd on behalf of IJS Publishing Group Ltd. This is an open access article under the CC BY-NC-ND license

(<http://creativecommons.org/licenses/by-nc-nd/4.0/>).

[9].

2. Case presentation

We present a 23-year old female who was referred to our facility with a 4 months history of epigastric pain worse on food ingestion, intermittent vomiting and loss of appetite. She had been passing melena stools and reported a 14 kg weight loss. No constipation or diarrhea and no prior history of any chronic illness, smoking or alcohol consumption and a negative family history of cancer. On physical examination, the patient was wasted with mild pallor, no jaundice, no lower limb edema. On abdominal examination, the patient had epigastric tenderness but difficult to appreciate any abdominal mass, no organomegally. Complete blood cell count done during admission showed mild anemia (Hemoglobin concentration of 9.5 g/dl).

Serum pancreatic enzyme tests done 3 months before admission were elevated: serum Lipase: 795.9 u/l (Normal range 13–60 u/l) and serum Amylase: 571.0 u/l (Normal range 40–140 u/l). The patient was managed for acute pancreatitis based on the clinical features and elevated pancreatic enzymes but there was no improvement symptomatically. Renal and liver function tests were normal.

Initial abdominal ultrasound scan done 3 months prior to admission showed an echo-complex pancreatic head mass. At admission esophagogastroduodenoscopy and abdominal CT scan were done. Esophagogastroduodenoscopy (Fig. 1) showed features of duodenal intussusception. Abdominal Computed tomography scan (CT scan) (Fig. 2) showed an irregular mass arising from the gastric antrum with narrowing of the stomach lumen, with a bowel within bowel loop at the duodenum that appeared as a mass displacing the pancreatic head with pancreatic duct dilatation plus intrahepatic and extrahepatic duct dilatation.

The patient underwent an exploratory laparotomy. Gastroduodenal intussusception with a 6x7cm, well-circumscribed ulcerated mass arising from the gastric body acting as a lead point was found. (Fig. 3) The intussusception was reduced manually and gastric wedge resection of the tumor was done. Stomach was repaired in 2 layers hand sewn

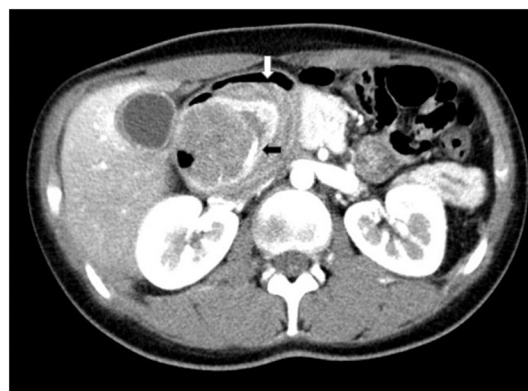

Fig. 2. Pre-operative Transverse contrast-enhanced Computer Tomography scan showing the stomach with a round mass (black arrow) protruding into the duodenum (white arrow) indicating gastroduodenal intussusception.

technique. No mesenteric lymph nodes or macroscopic metastatic lesions to the other intra-abdominal organs were found. Histological examination of the resected specimen was gastrointestinal stromal tumor with tumor free resection margins.

There was an uneventful postoperative recovery with marked improvement in symptoms. The patient was discharged on the fifth postoperative day. The patient had no complaints on review 1 month later with serum amylase and lipase of 178.3 U/l and 133.3 U/l respectively. Review at 3 months was unremarkable. She was referred to the Uganda Cancer Institute for further management and oncologic follow up.

3. Discussion

Gastroduodenal intussusceptions are a rare entity that account for <10% of all adult intussusceptions. Different types of lesions have been implicated in previous reported cases of gastroduodenal intussusceptions including; GISTs, gastric polyps, gastric lipomas, gastric

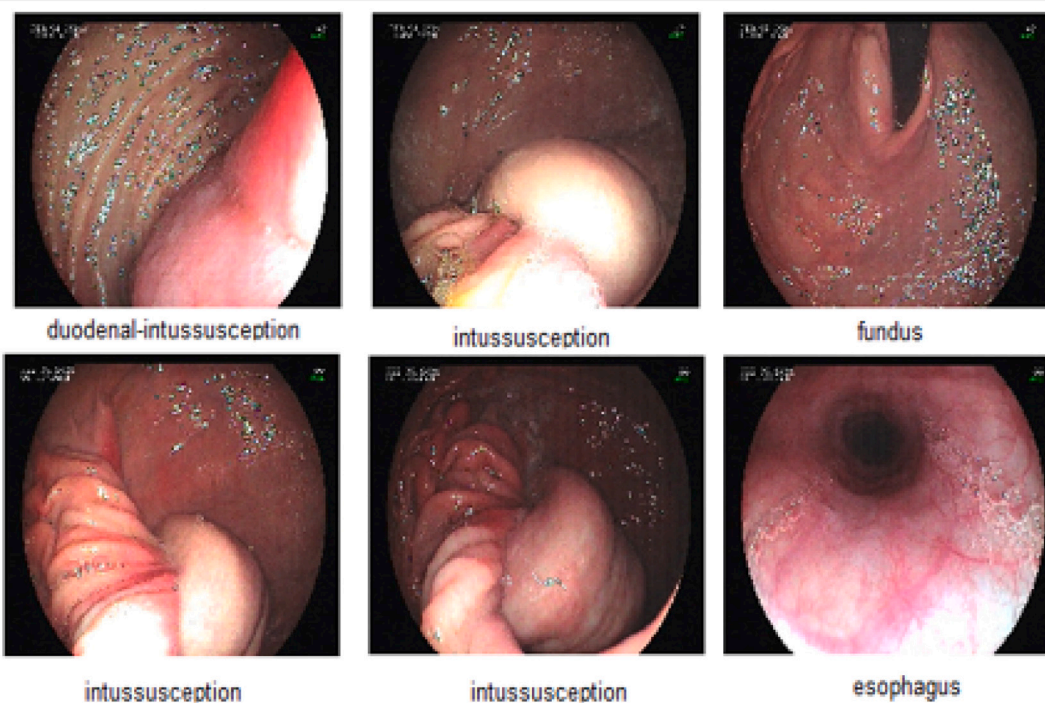


Fig. 1. Esophagogastroduodenoscopy findings showing duodenal intussusception.

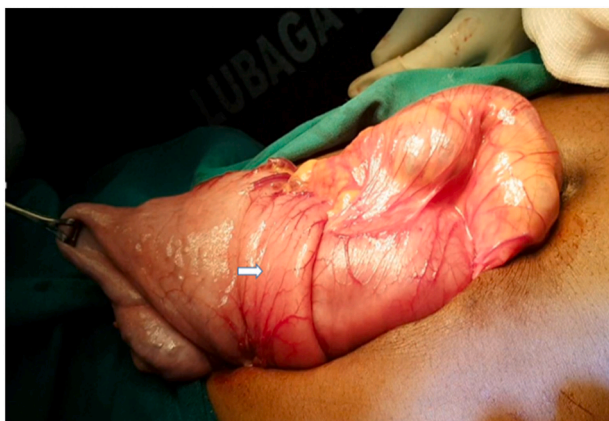

Fig. 3. Intraoperative photograph showing the stomach invaginating into the duodenum distally (white arrow).

carcinoma, gastric schwannoma and giant Brunner gland hamartoma [10–13]. GIST tumors are the most common cause of gastroduodenal intussusception. At 23 years, this patient is younger than the other previously reported cases of GISTs causing gastroduodenal intussusception (Mean age 64.5, median age 65 and range 29–95 years) [14,15].

Pancreatitis as a complication of intussuscepted gastric GIST tumors is a rare entity that has been reported in a few cases previously [13,16]. There have also been reports of pancreatitis as a complication of gastric polyps prolapsed into the duodenum [17]. The symptoms of pancreatitis in most of these cases resolved upon surgical excision of the obstructing tumor. It is possible that the intussuscepted tumor may have pressure effects on the ampulla of Vater obstructing the common ductal opening.

Gastroduodenal intussusceptions secondary to GISTs present a diagnostic dilemma due to their widely unspecific and variable presentation. Their Presentation may range from acute, subacute to chronic symptoms with clinical features such as intermittent mild to severe epigastric pain, nausea, vomiting, abdominal tenderness, palpable epigastric mass, weight loss plus gastrointestinal bleeding with anemia secondary to mucosal ulceration [14,15]. This patient had a chronic history of all these features with intermittent episodes of vomiting and increased epigastric pain which might be explained by possible recurrent, spontaneously reducible intussusceptions. The non-specific nature of the clinical presentation might explain the delayed diagnosis. The classic pediatric intussusception triad of abdominal pain, bloody stool and a palpable abdominal mass is rare in adult intussusceptions generally and was not present in this patient [15].

Due to the widely variable clinical features, diagnosis of adult intussusception is quite erratic with a pre-operative diagnostic rate of 40.7–50% that may delay timely interventions amidst disease progression [18]. Thus careful attention to the history, physical exam and utilization of imaging modalities is required. In this patient, prior abdominal ultrasound scan misdiagnosed the gastric tumor as a pancreatic head cyst due to its location and it did not detect the intussusception. The abdominal CT scan accurately diagnosed the gastroduodenal intussusception with its offending gastric tumor in the case presented. Various imaging modalities including ultrasonography, CT scans, MRI scans and endoscopy can be utilized to make a diagnosis. Of all imaging modalities, CT scan has been reported as the most useful with a diagnostic accuracy of 58–100% [18]. Characteristic features of intussusception on CT scan include a “sausage-shaped” mass in the longitudinal axis, and as a “target” mass in the transverse axis. CT scan also offers information on the location of the pathology and is important for staging purposes in case of malignant lesions. Abdominal ultrasound is also a useful diagnostic tool which can demonstrate the classical imaging features of intussusception but its accuracy is operator dependent [15]. Diagnosis in low resource countries is even more challenging especially in the rural areas due to limited accessibility and

unaffordability of the better imaging modalities such as CT scans and endoscopy [15].

Management of adult intussusceptions is predominantly surgical because they are mostly secondary to a pathologic lead point. Surgery is the treatment of choice for resectable GISTs aiming for R0 resection margins. This patient underwent open wedge resection of the gastric tumor. Several surgical approaches have been used in the management of gastric GISTs including; open, endoscopic and laparoscopic surgery. Laparoscopic resection is recommended for small and medium sized gastric GISTs and it has been associated with reduced length of hospital stay, low morbidity and mortality. Laparoscopic and endoscopic surgical procedures are available in Uganda and at our facility, but laparoscopic gastric wedge resection is not a routine practice. Resection of the offending gastric lesion in gastroduodenal intussusception complicated by pancreatitis results in resolution of the pancreatitis like what happened in the patient presented in this case report [19,20,21].

Imatinib mesylate is a tyrosine kinase inhibitor used in the management of GISTs. It has been shown to reduce recurrence rate significantly when used as an adjuvant to surgical resection (6% recurrence on imatinib vs. 17% without therapy at 12 months).

Prognosis of GISTs is related to the tumor size, mitotic rate, cellularity and nature of KIT mutations. Gastric GISTs carry a better prognosis. Yang et al. reported an overall median survival time of GISTs without metastasis of more than 60 months. Depending on the tumor biology, five year survival rate has been reported to be 48–70% [22,23].

4. Conclusion

Gastroduodenal intussusception is rare and may present with nonspecific clinical features. Pancreatitis may arise due to the compression effects on the ampulla of Vater or pancreatic head. A high index of suspicion is key in making a timely diagnosis.

Sources of funding

None.

Ethical approval

Not applicable.

Consent

Written informed consent was obtained from the patient for publication of this case report and accompanying images. A copy of the written consent form is available for review by the Editor-in-chief of this journal on request.

Research registration

Not applicable.

Guarantor

Dr. Okello Michael.

CRediT authorship contribution statement

Okello Michael Chief surgeon performed the surgery, patient follow up, conceptualization, writing the paper, editing, review, supervision and final approval.

Kayondo Derick Assisted in the surgery, patient follow up, conceptualization, writing the first draft, editing and approved the final manuscript.

Ocama Ponsiano Reviewed the manuscript for important intellectual content and approved the final manuscript.

Provenance and peer review

Not commissioned, externally peer-reviewed.

Declaration of competing interest

None.

References

- [1] M. Miettinen, J. Lasota, Gastrointestinal stromal tumors – definition, clinical, histological, immunohistochemical, and molecular genetic features and differential diagnosis, *Virchows Arch.* 438 (2001) 1–12.
- [2] I. Sugár, B. Forgács, G. István, G. Bognár, Z. Sápy, P. Ondrejka, Gastrointestinal stromal tumors (GIST), *Hepato-Gastroenterology* 52 (2005) 409–413.
- [3] G. Lamba, R. Gupta, B. Lee, S. Ambrale, D. Liu, Current management and prognostic features for gastrointestinal stromal tumor (GIST), *Exp. Hematol. Oncol.* 1 (2012) 14.
- [4] K. Søreide, O.M. Sandvik, J.A. Søreide, V. Giljaca, A. Jureckova, V.R. Bulusu, Global epidemiology of gastrointestinal stromal tumours (GIST): a systematic review of population-based cohort studies, *Cancer Epidemiol.* 40 (2016) 39–46.
- [5] D.Y. Yang, X. Wang, W.J. Yuan, Z.H. Chen, Metastatic pattern and prognosis of gastrointestinal stromal tumor (GIST): a SEER-based analysis, *Clin. Transl. Oncol.* 21 (2019) 1654–1662.
- [6] A. Zubaidi, F. Al-Saif, R. Silverman, Adult intussusception: a retrospective review, *Dis. Colon Rectum* 49 (2006) 1546–1551.
- [7] A. Gupta, S. Gupta, A. Tandon, M. Kotru, S. Kumar, Gastrointestinal stromal tumor causing ileo-ileal intussusception in an adult patient a rare presentation with review of literature, *Pan Afr. Med. J.* 8 (2011) 29.
- [8] K. Yamauchi, M. Iwamuro, E. Ishii, M. Narita, N. Hirata, H. Okada, Gastroduodenal intussusception with a gastric gastrointestinal stromal tumor treated by endoscopic submucosal dissection, *Internal Med. (Tokyo, Japan)* 56 (2017) 1515–1519.
- [9] R.A. Agha, T. Franchi, C. Sohrabi, G. Mathew, for the SCARE Group, The SCARE 2020 guideline: updating consensus Surgical CAse REport (SCARE) guidelines, *Int. J. Surg.* 84 (2020) 226–230.
- [10] B. Sankaranunni, D. Ooi, T. Sircar, R. Smith, J. Barry, Gastric lipoma causing gastroduodenal intussusception, *Int. J. Clin. Pract.* 55 (2002) 731–732.
- [11] J.H. Yang, M. Zhang, Z.H. Zhao, Y. Shu, J. Hong, Y.J. Cao, Gastroduodenal intussusception due to gastric schwannoma treated by billroth II distal gastrectomy: one case report, *World J. Gastroenterol.* 21 (2015) 2225–2228.
- [12] T. Suda, Y. Hodo, Y. Shiota, Gastroduodenal intussusception of a gastric carcinoma, *Dig. Endosc.* 31 (2019) e38–e39.
- [13] M.S. Yildiz, A. Doğan, I.H. Koparan, M.E. Adin, Acute pancreatitis and gastroduodenal intussusception induced by an underlying gastric gastrointestinal stromal tumor: a case report, *J. Gastric. Cancer* 16 (2016) 54–57.
- [14] M. Đokić, J. Novak, M. Petrić, B. Ranković, M. Štabuc, B. Trotovšek, Case report and literature review: patient with gastroduodenal intussusception due to the gastrointestinal stromal tumor of the lesser curvature of the gastric body, *BMC Surg.* 19 (2019) 158.
- [15] P. Ssentongo, M. Egan, T.E. Arkorful, et al., Adult intussusception due to gastrointestinal stromal tumor: a rare case report, comprehensive literature review, and diagnostic challenges in low-resource countries, *Case Rep. Surg.* 2018 (2018), 1395230.
- [16] P.G. White, H. Adams, H.M. Sue-Ling, D.J. Webster, Case report: gastroduodenal intussusception — an unusual cause of pancreatitis, *Clin. Radiol.* 44 (1991) 357–358.
- [17] R.A. de la Cruz, J.C. Albillos, J.M. Oliver, P. Dhimes, T. Hernandez, M.A. Trapero, Prolapsed hyperplastic gastric polyp causing pancreatitis: case report, *Abdom. Imaging* 26 (2001) 584–586.
- [18] A. Marinis, A. Yiallourou, L. Samanides, et al., Intussusception of the bowel in adults: a review, *World J. Gastroenterol.* 15 (2009) 407–411.
- [19] O. Jones, D. Monk, T. Balling, A. Wright, Acute pancreatitis secondary to a prolapsed gastric fundal GIST, *Int. J. Surg. Case Rep.* 3 (2012) 82–85.
- [20] M. Okello, G. Tumusiime, V. Nabimanya, S. Baguma, P. Ocama, Pioneering endoscopic retrograde cholangiopancreatography in a Sub Saharan African hospital: a case series, Available from: *Int. J. Surg. Open* 15 (2018) 14–17 <https://doi.org/10.1016/j.ijso.2018.10.002>.
- [21] M. Galukande, J. Jombwe, Feasibility of laparoscopic surgery in a resource limited setting: cost containment, skills transfer and outcomes, *East Cent. Afr. J. Surg.* 16 (2) (2011) 112–117.
- [22] Y. Wu, X. Zhu, Y. Ding, Diagnosis and treatment of gastrointestinal stromal tumors of the stomach: report of 28 cases, *Ann. Clin. Lab. Sci.* 37 (2007) 15–21.
- [23] G. Burkill, M. Badran, O. Al-Muderis, et al., Malignant gastrointestinal stromal tumor: distribution, imaging features, and pattern of metastatic Spread1, *Radiology* 226 (2003) 527–532.