

# Correlations of Scapular Dimensions: A Tool to Identify Scapulae with Completely Ossified Superior Transverse Scapular Ligaments and Suprascapular Neuropathy

**Adesanya Olamide Adewale**

Kampala International University - Western Campus

**Okeniran Olatayo Segun**

Kampala International University - Western Campus

**Ibe Michael Usman**

Kampala International University - Western Campus

**Ann Lemuel Monima**

Kampala International University - Western Campus

**Eric Simidi Kegoye**

Kampala International University - Western Campus

**Keneth Iceland Kasozi**

Kampala International University - Western Campus

**Halima Nalugo**

Mbarara University of Science and Technology

**Fred Ssempijja** (✉ [kalanzifr@yahoo.com](mailto:kalanzifr@yahoo.com))

Kampala International University - Western Campus <https://orcid.org/0000-0003-1849-7185>

---

## Research article

**Keywords:** Suprascapular notch, Completely Ossified Superior Transverse Scapular Ligament, Scapular dimensions, Suprascapular nerve Entrapment Syndrome, Anatomical variation

**DOI:** <https://doi.org/10.21203/rs.3.rs-55406/v1>

**License:**  This work is licensed under a Creative Commons Attribution 4.0 International License.

[Read Full License](#)

---

# Abstract

**Background.** A better understanding of the anatomy of the suprascapular notch and relationship with scapular dimensions are vital in the diagnosis, prevention, and assessment of the suprascapular nerve (SN) entrapment syndrome. Our purposes were to classify the suprascapular notches, determine the prevalence of completely ossified superior transverse scapular ligament, scapular dimensions, and their relationship among the different types of the suprascapular notch (SSN).

**Methods:** An experimental study in which the SSN types and scapular dimensions were determined using previous methods. Statistical analyses were done using GraphPad Prism v.6 and MS Excel Version 2019, one-way ANOVA was used to compare and Spearman's correlation coefficient was used to evaluate the correlation of scapular dimensions.

**Results:** The superior transverse scapular ligament (STSL) was completely ossified in 8% of cases. There were no significant differences between the scapular dimensions for the different SSN types. For type VI SSN there is a strong negative correlation between A, B against D. There are strong (positive or negative) correlations between types I and III from type VI for A-axis; types I, III from VI for B; type IV and VI for C axis; and type III and VI for D axis.

**Conclusions:** The prevalence of the completely ossified STSL in our study was moderately high; the correlation studies suggest that the scapular dimensions could be a valuable tool in the prediction, diagnosis, prevention, and assessment of the SN neuropathy due to the scapulae with the completely ossified superior transverse scapular ligaments (type VI SSN). Further studies on correlation analyses of scapular dimensions and characteristics of suprascapular notches are vital.

## Background

Anatomical variations and anomalies involving the suprascapular nerve (SSN) e.g. of suprascapular notch variations are important in the management and prevention of the SSN entrapment syndrome, and bony and brachial plexus injuries, furthermore, this knowledge is important for clinicians and surgeons that carry out diagnoses, assessment, management and surgical interventions at the shoulder region and in the prevention of this disorder. [1–3]. The suprascapular notch (SSN) forms a depression on the lateral aspect of the superior border of the scapula and located medial to the coracoid process [4], is bridged by the superior transverse scapular ligament (STSL), which may sometime be ossified with a resultant conversion of the notch into a foramen [4]. This foramen serves as a passage to the suprascapular nerve (SN) that supplies sensory branches to the rotator cuff and motor branches to the supraspinatus, and infraspinatus muscles [4, 5], it also provides sensory innervation to the acromioclavicular joint and ligaments, glenohumeral joint and associated ligaments [6]. Anatomical variations of the SSN were previously classified into six types, by Rengachary et al., 1979: type I (absent notch or shallow notch), II (shallow V notch), III (U notch), IV (deep V notch), V (partial ossification of superior transverse scapular ligaments) and VI (complete ossification of superior transverse scapular ligaments) based on their

morphologic and geometric features [7]. These variations and the ossification of the STSL are major risk factors for suprascapular neuropathy due to entrapment of the SN [6–8], a serious issue especially among individuals who are involved in violent overhead activities, such as volleyball, basketball, baseball, tennis players [9–11]. The SN neuropathy associated with anatomical variation of SSN was first described by Kopell and Thompson in 1959, and today approximately 1–2% of all shoulder pains arise from the syndrome with signs and symptoms such as weakness of the arm, inability to properly externally rotate and abduct the arm, and atrophy of the infraspinatus and supraspinatus muscles [9, 11]. Therefore, the size and shape of the suprascapular notch can predispose one to an SN entrapment syndrome with the neuropathy being more common among individuals with smaller SSN than individuals with larger SSN [4, 7, 9, 12]. The small notches of type III and IV are more frequently associated with the impingement than in large ones of type II [4, 7, 12]. The size of the SSN also parallels the size of the foramen such that a larger bony notch (type II) results in a larger foramen and vice versa, supporting this observation was the fact that type II had the biggest foramen, type III the intermediate, and type IV SSN had the smallest foramen [7, 13].

Among the 211 scapulae of the Americans, Type III was the most common (48%) and type IV was the least common (3%), type I, II, V, and VI were 8, 31, 6, and 4 percent respectively, with 4% of the SSNs having the completely ossified superior transverse scapular ligaments (type VI) [7]. The SSNs of Greeks on 423 dried scapulae found the least number of the scapulae (0%) being associated with the type VI, and the majority (42% each) were seen in type II, and III scapulae, with types I (No notch), IV and V being seen in 8.3, 7, and 0.7% of the population respectively. They stipulated that narrow SSNs in combination with anomalous STSL are associated with SN entrapment syndrome, and classifying the SSN using anatomical variations of the SSN simplifies the clinician's work when they incorporated radiography, and perhaps be able to correlate SN entrapment with a specific SSN type [14]. A study by [4] examining 415 dry scapulae of Indian origin found the following types SSNs: 10% had the type VI (completely ossified superior transverse scapular ligaments), types IV and V were the least common (with 4% each), type III was the most common (52%), and types I, and II contributed 20, and 10% respectively [4]. The study re-emphasized the role of complete ossification of the STSL, formation of the suprascapular foramen, and other morphometric variations of the SSN as the major causes of the SN entrapment syndrome [4]. A Kenyan study on 138 dry scapulae of the East Africans (Kenyans) found that type III SSN was the most prevalent (29%) in tandem with other studies, with type VI being the least prevalent (3%), and the occurrence of types I, II, IV, and V is 22%, 21%, 6%, and 19% respectively. People having scapulae with lack of SSNs (an anatomical variation that occurs in scapulae being associated with SSNs), and type III (scapulae having smaller Suprascapular foramina) are more predisposed to SN entrapment syndrome [15].

A polish study determined a correlation between morphometry of the SSN and anthropometric measurements of the scapula on 86 scapulae found that 7% of them had completely ossified STSL. There was no statistically significant difference between anthropometric measurements of the scapulae of different SSN types, the maximal depth (MD) of the SSN correlated with the morphological length of the scapulae; however, it negatively correlated with scapular width-length index (WLI) [9]. An Italian study

performed by [16] on 500 dry scapulae to determine the morphometry of the SSN, correlation of the SSN with scapular dimensions, and clinical relevance found the following frequencies: Type I 12.4%, type II 19.8%, type III 22.8%, type IV 31.1%, type V 10.2%, type VI 3.6%. The study found that patient's scapular dimensions were not related to the characteristics of the SSN such as shape and type of the SSN, and the findings also suggested that the entrapment syndrome is more likely to be associated with a type III notch because of its specific features and characteristics (smaller Suprascapular foramina, numerical frequency of type III scapulae, etc) [16], a finding that is in tandem with previous studies by [7, 13, 15]. The relationship between SSN types and basic morphometric scapular dimensions and the clinical value of this relationship in identifying scapulae with completely ossified STSL is not known in our various communities, and this knowledge would be vital for making a clinical diagnosis, assessment, and prevention of SN entrapment syndrome easier.

We aimed to classify the suprascapular notches, determine the prevalence of the completely ossified superior transverse scapular ligament, assess the anthropometric scapular dimensions and their relationship among the different types of SSN as a tool in diagnosing suprascapular neuropathy.

## Methods

### Study Design

This was an experimental qualitative and quantitative study conducted to classify the suprascapular notches, determine the prevalence of the completely ossified superior transverse scapular ligament, assess the anthropometric scapular dimensions, and their relationship among the different types of SSN. It was conducted at the Museum of the Department of Human Anatomy of Kampala International University, Western Campus located in Western Uganda. The samples were sourced from institutional cadavers of Kampala International University, western campus. Our research was conducted in compliance with the Helsinki Declaration with the formal approval of the Scientific and Ethics review committee of Kampala International University Western Campus, Uganda (Nr.UG-REC-023/202014).

The number of scapulae (sample size) used in our study was estimated using the following standard statistical equation [17]:  $N = 4(Z_{crit})^2 p(1-p)$

$D^2$

Where  $p$  = pre-study estimate of the proportion of scapulae with completely ossified STSL (10%),  $N$  = sample size of the study group (?),  $Z_{crit}$  = Standard Normal Deviate corresponding to 95% significance criteria and confidence interval (1.96),  $D$  = total width of the expected confidence interval ( $\pm 20$ ). The equation yields a sample size of  $N = 35$ . Because the sample size we calculated ( $N = 35$ ) was not too large and could feasibly be studied, we increased the sample size of the study to  $N = 50$  to avoid results that would not be reproducible due to the use of smaller sample size [17]. The fifty (50) dry human scapulae were obtained from adult donors of unknown gender and were randomly selected using a

random number algorithm in MS Excel Version 2019 and used as the sample specimen (n = 50) for the study. The broken scapulae were excluded from the study.

### **Determination of the proportion of suprascapular notch types and scapula dimensions**

The shapes of the scapular notches were classified using Renganchary's system as types I, II, III, IV, V, and VI [7], similar to a previous study [16]. Representative photographs of the various notch types were taken using a digital camera (Olympus Stylus 600 6MP). The results on different types of SSNs among 50 scapulae were recorded as counts and percentages and these were compared with existing data from previous studies.

The morphological dimensions of scapulae were assessed using previous methods [16, 18] by measuring two distances for each scapula body (scapula length and width): (i) scapula length: the major longitudinal axis of the scapular body, measured from the medial angle to the inferior angle of the scapula (A axis); (ii) scapula width: the major transversal axis of the scapular body, measured from the lowest point of the glenoid to the vertebral border of the scapula at the level of the smooth surface over which the trapezius glides (B axis) [16, 18] (Fig. 3). The morphological dimensions of glenoid fossa were assessed using previous methods [16, 18] by measuring two distances for each glenoid fossa (glenoid length and width): (i) glenoid length: the major longitudinal axis of the glenoid fossa, measured from the supraglenoid tubercle to the lowest point of the glenoid (distance C); (ii) glenoid width: the major transversal axis of the glenoid fossa, measured at its widest distance from the midline of the anterior to the midline of the posterior [16, 18] (Fig. 3). All the measurements were performed thrice using a digital Vernier caliper (Mitutoyo 500 – 153 Absolute Caliper 0-300 mm Range-SPC) and recorded in centimeters.

## **Statistical analysis**

All statistical analyses were done using GraphPad Prism v.6 and MS Excel Version 2019 and presented in tables and bar graphs. Discrete/categorical variables (the types of the scapular notches) were reported as percentages and numerical counts; continuous variables (scapular dimensions of each SSN type) were reported using descriptive statistics as mean, median, standard deviation, and range. Ordinary one-way ANOVA (Tukey's multiple comparisons test) was used to compare the dimensions in different types of notches. Spearman's rank correlation coefficient was used to evaluate the correlation of dimensions in different types of notches. A value of  $p < 0.05$  was considered statistically significant.

## **Results**

### **Prevalence of scapulae with completely ossified STSL is moderate and scapulae with type III SSN are the most prevalent in the Ugandan population**

In examining the frequencies and percentages of SSN types, the highest prevalence is of type III (51%) among the whole population. The superior transverse scapular ligament is completely ossified in 8% of cases with an absence of the notch (type VI) (details in Fig. 1, 2 and Table 1).

Table 1

Comparison of the percentages of the different types of suprascapular notch presented in the literature

Author	Type I	Type II	Type III	Type IV	Type V	Type VI	Population (N)
Rengachary et al., 1979 [7]	8%	31%	48%	3%	6%	4%	American (211)
Natsis et al., 2007 [14]	8.3%	42%	42%	7%	0.7%	0%	Greek (423)
Sinkeet et al., 2010 [15]	22%	21%	29%	6%	19%	3%	Kenyan (138)
M. Polguj et al, 2011[9]						7%	Polish (86)
Albino et al, 2013[16]	21.4%	19.8%	22.8%	31.1%	10.2%	3.6%	Italian (500)
Polguj et al., 2013[11]	24.2%	1.9%	56.2%	4.7	4.7%	0%	Polish (308)
Kannan, 2014[4]	20%	10%	52%	4%	4%	10%	Indian (415)
Our study, 2020	16.3%	12.2%	51%	12.2%	4.1%	8.2%	Ugandan (50)
N = number of the sample							

Figure 1 [here](#)

Figure 2 [here](#)

Table 1 [here](#)

### Scapulae of type IV showed the largest while scapulae of types II and VI SSN had the smallest mean scapular length, glenoid length, and width

The scapulae with type IV SSN had the largest mean scapular length (15.55 cm), glenoid length (3.817 cm), glenoid width (2.95 cm), scapulae with type VI SSN had the largest scapular width (10.8 cm). Scapulae with type II SSN had the lowest mean scapular length and width (11.9, 8.9 cm respectively); while those with type VI SSN had the lowest mean glenoid length and width (3.325 and 2.250 cm respectively). Descriptive statistics related to the morphometric dimensions of the scapulae of the SSN types are summarized in Fig. 3, and Table 2.

Table 2

Descriptive analysis of the morphometric dimensions of the scapula of the suprascapular notch types

<b>SSN Type</b>	<b>Mean (cm)</b>	<b>Median (cm)</b>	<b>Standard deviation</b>	<b>Range (cm)</b>
<b>Type I</b>				
A	15.14	15.50	1.004	13.50–16.00
B	10.39	11.00	1.233	8.300–11.30
C	3.613	3.650	0.3758	3.000–4.000
D	2.425	2.550	0.2659	2.000-2.600
<b>Type II</b>				
A	11.90	11.90	0.2098	11.60–12.20
B	8.817	8.900	1.233	8.300-9.000
C	3.433	3.400	0.1366	3.300–3.600
D	2.283	2.250	0.09832	2.200–2.400
<b>Type III</b>				
A	14.37	14.50	0.9320	13.20–15.40
B	9.970	10.30	0.6996	9.000-10.60
C	3.448	3.500	0.2213	3.100–3.700
D	2.735	2.600	0.5449	2.200–3.500
<b>Type IV</b>				
A	15.55	15.90	0.6442	14.50–16.00
B	10.78	11.00	0.7885	9.500–11.50
C	3.817	3.900	0.2137	3.500-4.000
D	2.950	2.800	0.5282	2.400–3.600
<b>Type V</b>				
A	15.50	15.50	0.7071	15.00–16.00
B	10.45	10.45	0.4950	10.10–10.80
C	3.650	3.650	0.2121	3.500–3.800

A = major longitudinal axis of the scapular body; B = major transversal axis of the scapular body; C = major longitudinal axis of the glenoid fossa; D = major transversal axis of the glenoid fossa.

SSN Type	Mean (cm)	Median (cm)	Standard deviation	Range (cm)
D	2.650	2.650	0.2121	2.500–2.800
<b>Type VI</b>				
A	13.45	13.20	2.402	11.40–16.00
B	10.10	9.850	1.667	8.700–12.00
C	3.325	3.300	0.1258	3.200–3.500
D	2.275	2.250	0.09574	2.200–2.400
A = major longitudinal axis of the scapular body; B = major transversal axis of the scapular body; C = major longitudinal axis of the glenoid fossa; D = major transversal axis of the glenoid fossa.				

Figure 3 [here](#)

Table 2 [here](#)

**The morphometric dimensions of scapulae with type VI SSN were not statistically different from those of the other suprascapular notch types**

The scapula length (A) of type VI SSN was not statistically different ( $P > 0.05$ ) from those of types I, II, III, and V; but was statistically different ( $P = 0.0342$ ) from that of type IV. The scapula width (B) of type VI SSN was not statistically different from the rest of the SSN types. The glenoid length (C) of type VI SSN was not statistically significantly different ( $P > 0.05$ ) from types I, II, III, and V; but was statistically different ( $P = 0.0312$ ) from that of type IV. The glenoid width (D) of type VI SSN was not statistically different from the rest of the SSN types. Details of the multiple comparisons on the morphometric dimensions of scapulae of the SSN types are in Fig. 4 and **Additional file 1**.

Figure 4 [here](#)

**There were strong positive correlations between the scapular length and width for all the SSN types**

For all the SSN types in general, there was a strong positive relationship ( $r = 0.920547$ ) between A and B; and moderate positive relationships for the remaining correlations between the variables (details in Table 3).

Table 3  
Correlation coefficient for suprascapular notch and scapular morphometric measurements

	A	B	C	D
A	1			
B	0.920547	1		
C	0.576491	0.674716	1	
D	0.430148	0.513304	0.690425	1

A = major longitudinal axis of the scapular body; B = major transversal axis of the scapular body; C = major longitudinal axis of the glenoid fossa; D = major transversal axis of the glenoid fossa.

Table 3 [here](#)

**There were strong positive correlations between scapular length and width and strongly negative correlations between scapular length, width against glenoid width for scapulae with type VI SSN**

In general, there were strong positive correlations ( $r = 0.7-1$ ) among dimensions A, B, C, and D of types I, III, and IV. In SSN type VI there was a strong positive relationship ( $r = 0.997069$ ) between A and B axes, strong negative relationships ( $r = -0.89137, -0.877$ ) between A and D, B and D respectively, as well as weak negative correlations ( $r = -0.22608, -0.22243, -0.20751$ ) between A and C, B and C, C and D respectively (details in Table 4)

Table 4  
Correlation coefficient of each SSN type of different morphometric dimensions

	A	B	C	D
<b>Type 1</b>				
A	1			
B	0.988912	1		
C	0.850258	0.841722	1	
D	0.980342	0.98981	0.768303	1
<b>Type 2</b>				
A	1			
B	0.597196	1		
C	0.279145	0.143823	1	
D	-0.29093	0.537122	0.049629	1
<b>Type 3</b>				
A	1			
B	0.972381	1		
C	0.692801	0.828927	1	
D	0.401379	0.599059	0.927954	1
<b>Type 4</b>				
A	1			
B	0.970608	1		
C	0.980641	0.98719	1	
D	0.767034	0.881222	0.85935	1
<b>Type 5</b>				
A	1			
B	no value	1		
C	no value	no value	1	

no value = #DIV/0! error value because the standard deviation of the values equals zero in Type V suprascapular notch; SSN = suprascapular notch. A = major longitudinal axis of the scapular body; B = major transversal axis of the scapular body; C = major longitudinal axis of the glenoid fossa; D = major transversal axis of the glenoid fossa.

	A	B	C	D
D	no value	no value	no value	1
<b>Type 6</b>				
A	1			
B	0.997069	1		
C	-0.22608	-0.22243	1	
D	-0.89137	-0.877	-0.20751	1
no value = #DIV/0! error value because the standard deviation of the values equals zero in Type V suprascapular notch; SSN = suprascapular notch. A = major longitudinal axis of the scapular body; B = major transversal axis of the scapular body; C = major longitudinal axis of the glenoid fossa; D = major transversal axis of the glenoid fossa.				

Table 4 here

**There were strongly positive and negative correlations for scapular and glenoid length of type VI SSN compared to the scapular of other SSN types**

There was a strong positive correlation ( $r = 0.984199$ ) between A of type III and A of type VI, a strong negative relationship ( $r = -0.76664$ ) between A of type I and A of type VI. There was a strong positive correlation ( $r = 0.994792$ ) between B of type III and B of type VI, a strong negative relationship ( $r = -0.78853$ ) between B of type I and B of type VI, and a moderate negative relationship ( $r = -0.61113$ ) between B of type II and B of type VI. There was a strong positive correlation ( $r = 0.723339$ ) between C of type IV and C of type VI. There was a moderately positive correlation ( $r = 0.636364$ ) between D of type I and D of type VI, and a strong negative relationship ( $r = -0.72408$ ) between D of type III and D of type VI (details in Table 5).

Table 5  
Correlation coefficient of each morphometric dimension for scapula of different suprascapular notch types

	Type 1	Type 2	Type 3	Type 4	Type 5	Type 6
<b>A</b>	1					
Type 1						
Type 2	-0.20484	1				
Type 3	-0.08035	-0.25059	1			
Type 4	-0.18342	0.192408	0.294996	1		
Type 5	no value	no value	no value	no value	1	
Type 6	-0.76664	-0.33322	0.984199	-0.05088	no value	1
<b>B</b>						
Type 1	1					
Type 2	0.051943	1				
Type 3	-0.03034	-0.4133	1			
Type 4	-0.09387	0.758566	0.035569	1		
Type 5	no value	no value	no value	no value	1	
Type 6	-0.78853	-0.61113	0.994792	-0.21097	no value	1
<b>C</b>						
Type 1	1					
Type 2	-0.41302	1				
Type 3	0.455726	0.368522	1			
Type 4	-0.04801	0.593675	-0.15245	1		
Type 5	no value	no value	no value	no value	1	
Type 6	0.319764	0.187317	-0.2163	0.723339	no value	1
<b>D</b>						
Type 1	1					

no value = #DIV/0! error value because the standard deviation of the values equals zero in Type V suprascapular notch. A = major longitudinal axis of the scapular body; B = major transversal axis of the scapular body; C = major longitudinal axis of the glenoid fossa; D = major transversal axis of the glenoid fossa.

	Type 1	Type 2	Type 3	Type 4	Type 5	Type 6
Type 2	-0.116	1				
Type 3	0.252832	-0.5579	1			
Type 4	0.129556	0.94353	-0.45142	1		
Type 5	no value	no value	no value	no value	1	
Type 6	0.636364	-0.09091	-0.72408	0.080013	no value	1
no value = #DIV/0! error value because the standard deviation of the values equals zero in Type V suprascapular notch. A = major longitudinal axis of the scapular body; B = major transversal axis of the scapular body; C = major longitudinal axis of the glenoid fossa; D = major transversal axis of the glenoid fossa.						

Table 5 here

## Discussion

The scapulae with type III suprascapular notch (SSN) were the most prevalent in our study (51%) and the prevalence of complete ossification of the superior transverse scapular ligament (STSL) was moderately high (8.2%). These findings concur with those from previous studies in Americans, Greeks, Kenyans, Polish, Italians, Indians where the values were 22.8–56.2% and 0–10% respectively, Table 1 [4, 7, 9, 11, 14–16]. Although there are dynamic statistics regarding the prevalence of complete ossification of STSL of our study in comparison to other results i.e twice the mean prevalence of the previous studies (4% ), eight times more than in Greeks (0%), about twice that of Americans (4%), Italians (3.6) and Kenyans (3%), similar to that of the Polish (7%) and Indians (10%) Table 1 [4, 7, 9, 11, 14–16], but the prevalence of completely ossified STSL in our study (8.2%) falls within the range of the previous results (0–10%) [7, 15, 16].

Type VI SSN (complete ossification of STSLs) [4, 7] is a major risk factor for suprascapular neuropathy due to SN entrapment [6–8]. The scapulae with completely ossified STSLs (type VI) of our study could not be differentiated from other SSN types using the basic morphometric scapular dimensions (A, B, C, and D) i.e. the dimensions were statistically similar for all the SSN types, except for type IV SSN. Our findings concur with previous findings that showed no significant differences between the scapular dimensions of different SSN types [9, 16]. This is an indication that the morphological dimensions of the scapula body and glenoid fossa are not straight-forward predictors of the occurrence of SN entrapment syndrome from complete ossification of the STSL associated with type VI SSN. It is worthy to note that types VI and IV SSN had statistically different morphological lengths of the scapula body (A) and glenoid fossa (C), this finding could be exploited in medicine in the prediction, diagnosis, and assessment of the SN Entrapment syndrome caused by either type IV or VI but because previous studies have shown both types as being associated with SN Entrapment syndrome [14], and because scapular width (B) and glenoid width (D) were similar for the two types, this finding is of less clinical value about SN neuropathy.

Furthermore, our study has shown that based on the morphological dimensions of the scapula (A, B, C, and D), it is generally not possible to differentiate scapulae of type III and IV from those with type I and II SSNs as all have similar scapular dimensions. Because people with a type IV and III SSNs are more predisposed to the SN entrapment syndrome than those with type I and II [7, 13, 15, 16], the study seems to suggest that our dimensions are of less value in the prediction of occurrence, proper diagnosis, and assessment of the SN entrapment syndrome associated with types III and IV SSN, and although our study established significantly different scapular body lengths between types II, III, and IV but this finding needs further exploration before we can conclude it as being useful in the identification of type II from SSN types that are associated with predisposition to SN neuropathy (III and IV).

For all SSN types in general, there is a strong direct connection between A and B axis; the more A increases, the greater the B axis via an exact linear rule, this finding was in tandem with [9] where the maximal depth (MD) of the SSN correlated with the morphological length of the scapulae [9]. However, most other morphometric measurements in this population indicate a moderate positive linear relationship via a fuzzy-firm linear rule, indicating that it is not very easy to use these relationships to predict the status of these dimensions in the population and that the patient's scapular dimensions were not related to the characteristics of the SSN such as shape and type of the SSN [16], a picture similar to the study by [9] where most of the other correlation relationships such as the moderate negative correlation (weak correlations) between the maximal depth (MD) of the SSN and scapular width-length index (WLI) were obtained [9]. In general, the patient's scapular dimensions were not related to the characteristic of the SSN (type of SSN) and thus the scapular dimensions are not necessary predictors of type of SSN in a given scapula and vice versa.

Considering all the six types of SSN in our study, scapulae with SSN types I, III, and IV have a direct connection between the dimensions A, B, C, and D of the scapula; as one variable increases in its values, the other variable also increases in its values through an exact linear rule, this relationship is consistent between A and B axes of type VI and concurs with [9] where a positive correlation between the maximal depth (MD) and the morphological length of the scapulae was seen. The rest of the correlations related to dimensions of SSN type VI are either strongly (A and D; B and D) or weakly negative indicating an inverse correlation also consistent with [9] where he found a negative correlation between the maximal depth (MD) of the SSN and scapular width-length index. This indicates that for type VI SSN, as the A and B axes increases, the D axis tends to decrease through an exact linear rule. This finding indicates that the relationship between scapular dimensions A, B against D can be exploited to find scapulae with SSN type VI and therefore can be exploited for the possible prediction of SN entrapment syndrome associated with it. There are strong (positive or negative) correlations between types I and III from type VI for A-axis; types I, III from VI for B; type IV and VI for the C axis; and type III and VI for the D axis. From the above findings it can be concluded that correlations from all the four morphological lengths of the scapula (A, B, C, and D): are strong and statistically significant, and therefore can be used to differentiate types I and III from type VI using the A axis B axis can identify types I, III from VI; C axis can be used to identify type IV from VI, and D axis can be used to identify type III from type VI SSN. These correlations show that correlation studies regarding scapular morphological dimensions (scapular length and width; glenoid length and

width) are strong and statistically significant in agreement with [9] but in contradiction with [16] that got weak correlation indices. The strong correlations obtained in our study could be of clinical value in the prediction, diagnosis, and assessment of SN entrapment syndrome associated with type VI SSN as suggested by [9] using the correlation between maximal depth of the scapular notch with the morphological length of the scapulae [9]. In general, the correlation analyses of our study have shown that the scapular dimensions (scapular length and width; glenoid length and width) might be of value in the diagnosis, assessment, and prevention of SN entrapment syndrome associated with scapulae of type III, IV and VI SSN emphasizing the clinical significance of scapula, glenoid and other related scapular dimensions in helping clinicians, radiologists, and orthopaedic surgeons. perform better with minimal complications [1–3]. However, the equation that can be used to predict the relationship of different scapular dimensions and the SSN types could not be determined. We recommend further research involving the evaluation of the correlation of scapular dimensions with characteristics of SSN such as shape, dimensions. There could be gender and age-related differences in the anatomical variations of scapulae and scapular dimensions, however, our study did not focus on this design.

## Conclusions

The prevalence of scapulae of type I, II, III, IV, V, and VI SSNs were similar to those from previous studies and the prevalence of the completely ossified STSL (type VI) in our study was moderately high (8.2%) similar to previous results. Although the patient's scapula dimensions were not directly related to their type of SSN, the correlation studies indicate that they could be a valuable tool in the prediction, diagnosis, prevention, and assessment of the SN entrapment syndrome associated with scapulae with the completely ossified superior transverse scapular ligaments (type VI SSN). Further studies involving correlation analyses of different scapular dimensions and different characteristics of suprascapular notches such as shape, dimensions are vital.

## Abbreviations

ANOVA Analysis of variance

SN Suprascapular nerve

SSN Suprascapular notch

STSL Superior transverse scapular ligament

## Declarations

### Ethics approval and consent to participate

Ethical approval was acquired from the Scientific and Ethics review committee of Kampala International University Western Campus, Uganda (Nr.UG-REC-023/202014).

## Consent for publication

Not applicable.

## Availability of data and materials

Data files can be accessed at <https://figshare.com/s/c624cecf6f2d9693165e>

## Competing interests

The authors declare that they have no competing interests.

## Funding

Not Applicable

## Authors' contributions

A.O.A, F.S, O.O.S, I. M.U conceptualized the study A.O.A, F.S, O.O.S, I. M.U, A.L.M designed the study. A.O.A, F.S, O.O.S, I. M.U, A.L.M, E.S.K collected the data. A.O.A, F.S, O.O.S, I. M.U, A.L.M, E.S.K, K.I.K, H.N conducted data analysis A.O.A, F.S, O.O.S, I. M.U, A.L.M, E.S.K, K.I.K interpreted the data A.O.A, F.S, O.O.S, I.M.U drafted the initial manuscript A.L.M, E.S.K, K.I.K, H.N reviewed it for intellectual content while analysis A.O.A, F.S, O.O.S, I.M.U, A.L.M, E.S.K, K.I.K, H.N approved it for publication and remain in agreement to be accountable to all aspects of the work. All the authors have read and agreed to the final manuscript.

## Acknowledgments

We thank the Laboratory technicians and Attendants of Kampala International University, western campus who offered assistance in the laboratory and museum whenever called upon during the study.

## References

- [1]. Kharay S, Sharma A, Singh P. Unusual morphology of scapulae: incidence and dimensions of ossified ligaments and supraspinous bony tunnels for clinical consideration. *Singapore Med J* [Internet]. 2016 Jan;57(01):29–32. Available from: <http://smj.org.sg/article/unusual-morphology-scapulae-incidence-and-dimensions-ossified-ligaments-and-supraspinous>
- [2]. Chaijaroonkhanarak W, Amarttayakong P, Ratanasuwan S, Kirirat P, Pannangrong W, Welbat JU, et al. Predetermining glenoid dimensions using the scapular dimensions. *Eur J Orthop Surg Traumatol* [Internet]. 2019 Apr 15;29(3):559–65. Available from: <https://doi.org/10.1007/s00590-018-2313-9>
- [3]. Rohman E, Gronbeck K, Tompkins M, Mittelsteadt M, Kirkham JA, Arciero RA. Scapular Spine Dimensions and Suitability as a Glenoid Bone Graft Donor Site. *Am J Sports Med* [Internet]. 2019 Aug 16;47(10):2469–77. Available from: <http://journals.sagepub.com/doi/10.1177/0363546519861965>

- [4]. Kannan U. Morphometric Study of Suprascapular Notch in Indian Dry Scapulae with Specific Reference to the Incidence of Completely Ossified Superior Transverse Scapular Ligament. *J Clin DIAGNOSTIC Res* [Internet]. 2014;8(3). Available from: [http://www.jcdr.net/article\\_fulltext.asp?issn=0973-709x&year=2014&volume=8&issue=3&page=7&issn=0973-709x&id=4089](http://www.jcdr.net/article_fulltext.asp?issn=0973-709x&year=2014&volume=8&issue=3&page=7&issn=0973-709x&id=4089)
- [5]. Ebraheim NA, Whitehead JL, Alla SR, Moral MZ, Castillo S, McCollough AL, et al. The suprascapular nerve and its articular branch to the acromioclavicular joint: an anatomic study. *J Shoulder Elb Surg* [Internet]. 2011 Mar;20(2):e13–7. Available from: <https://linkinghub.elsevier.com/retrieve/pii/S1058274610004040>
- [6]. Lädermann A, Lübbecke A, Mélis B, Stern R, Christofilopoulos P, Bacle G, et al. Prevalence of Neurologic Lesions After Total Shoulder Arthroplasty. *J Bone Jt Surgery-American Vol* [Internet]. 2011 Jul;93(14):1288–93. Available from: <http://journals.lww.com/00004623-201107200-00002>
- [7]. Rengachary SS, Burr D, Lucas S, Hassanein KM, Mohn MP, Matzke H. Suprascapular Entrapment Neuropathy: A Clinical, Anatomical, and Comparative Study. *Neurosurgery* [Internet]. 1979 Oct;5(4):447–51. Available from: <https://academic.oup.com/neurosurgery/article-lookup/doi/10.1227/00006123-197910000-00007>
- [8]. Bayramoglu A, Demiryörek D, Töccar E, Erbil M, Aldur MM, Tetik O, et al. Variations in anatomy at the suprascapular notch possibly causing suprascapular nerve entrapment: an anatomical study. *Knee Surgery, Sport Traumatol Arthrosc* [Internet]. 2003 Nov 1;11(6):393–8. Available from: <http://link.springer.com/10.1007/s00167-003-0378-3>
- [9]. Polguy M, Jędrzejewski KS, Podgórski M, Topol M. Correlation between morphometry of the suprascapular notch and anthropometric measurements of the scapula. *Folia Morphol (Warsz)* [Internet]. 2011 May;70(2):109–15. Available from: <http://www.ncbi.nlm.nih.gov/pubmed/21630232>
- [10]. Safran MR. Nerve Injury about the Shoulder in Athletes, Part 1. *Am J Sports Med* [Internet]. 2004 Apr 30;32(3):803–19. Available from: <http://journals.sagepub.com/doi/10.1177/0363546504264582>
- [11]. Polguy M, Sibiński M, Grzegorzewski A, Grzelak P, Majos A, Topol M. Variation in morphology of suprascapular notch as a factor of suprascapular nerve entrapment. *Int Orthop* [Internet]. 2013 Nov 27;37(11):2185–92. Available from: <http://link.springer.com/10.1007/s00264-013-2005-3>
- [12]. Bhatia DN, de Beer JF, van Rooyen KS, du Toit DF. Arthroscopic Suprascapular Nerve Decompression at the Suprascapular Notch. *Arthrosc J Arthrosc Relat Surg* [Internet]. 2006 Sep;22(9):1009–13. Available from: <https://linkinghub.elsevier.com/retrieve/pii/S0749806306007274>
- [13]. Zehetgruber H, H. N, T. L, Wurnig C. Suprascapular nerve entrapment. A meta-analysis. *Int Orthop* [Internet]. 2002 Dec 1;26(6):339–43. Available from: <http://link.springer.com/10.1007/s00264-002-0392-y>

- [14]. Natsis K, Totlis T, Tsikaras P, Appell HJ, Skandalakis P, Koebke J. Proposal for classification of the suprascapular notch: A study on 423 dried scapulas. *Clin Anat* [Internet]. 2007 Mar;20(2):135–9. Available from: <http://doi.wiley.com/10.1002/ca.20318>
- [15]. Sinkeet SR, Awori KO, Odula PO, Ogeng’o JA, Mwachaka PM. The suprascapular notch: Its morphology and distance from the glenoid cavity in a kenyan population. *Folia Morphol (Warsz)* [Internet]. 2010;69(4):241–5. Available from: <https://www.ajol.info/index.php/eaaj/article/view/77831>
- [16]. Albino P, Carbone S, Candela V, Arceri V, Vestri AR, Gumina S. Morphometry of the suprascapular notch: correlation with scapular dimensions and clinical relevance. *BMC Musculoskelet Disord* [Internet]. 2013 Dec 24;14(1):172. Available from: <http://bmcmusculoskeletdisord.biomedcentral.com/articles/10.1186/1471-2474-14-172>
- [17]. Eng J. Sample Size Estimation: How Many Individuals Should Be Studied? *Radiology* [Internet]. 2003 May;227(2):309–13. Available from: <http://pubs.rsna.org/doi/10.1148/radiol.2272012051>
- [18]. Gumina S, Albino P, Giaracuni M, Vestri A, Ripani M, Postacchini F. The safe zone for avoiding suprascapular nerve injury during shoulder arthroscopy: An anatomical study on 500 dry scapulae. *J Shoulder Elb Surg* [Internet]. 2011 Dec;20(8):1317–22. Available from: <http://dx.doi.org/10.1016/j.jse.2011.01.033>

## Figures

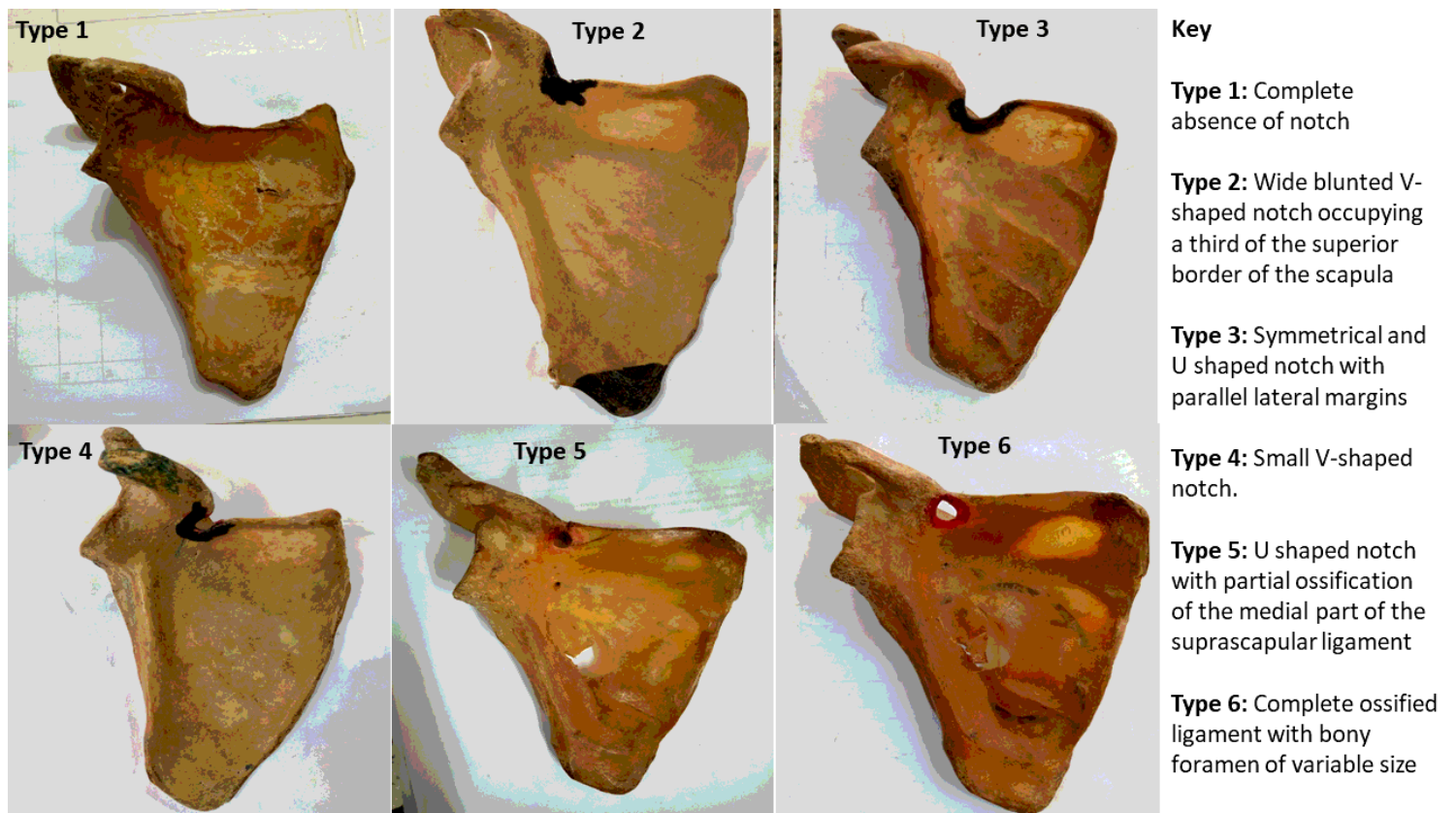


Figure 1

Photographs of the scapulae representing the suprascapular notch types of the study

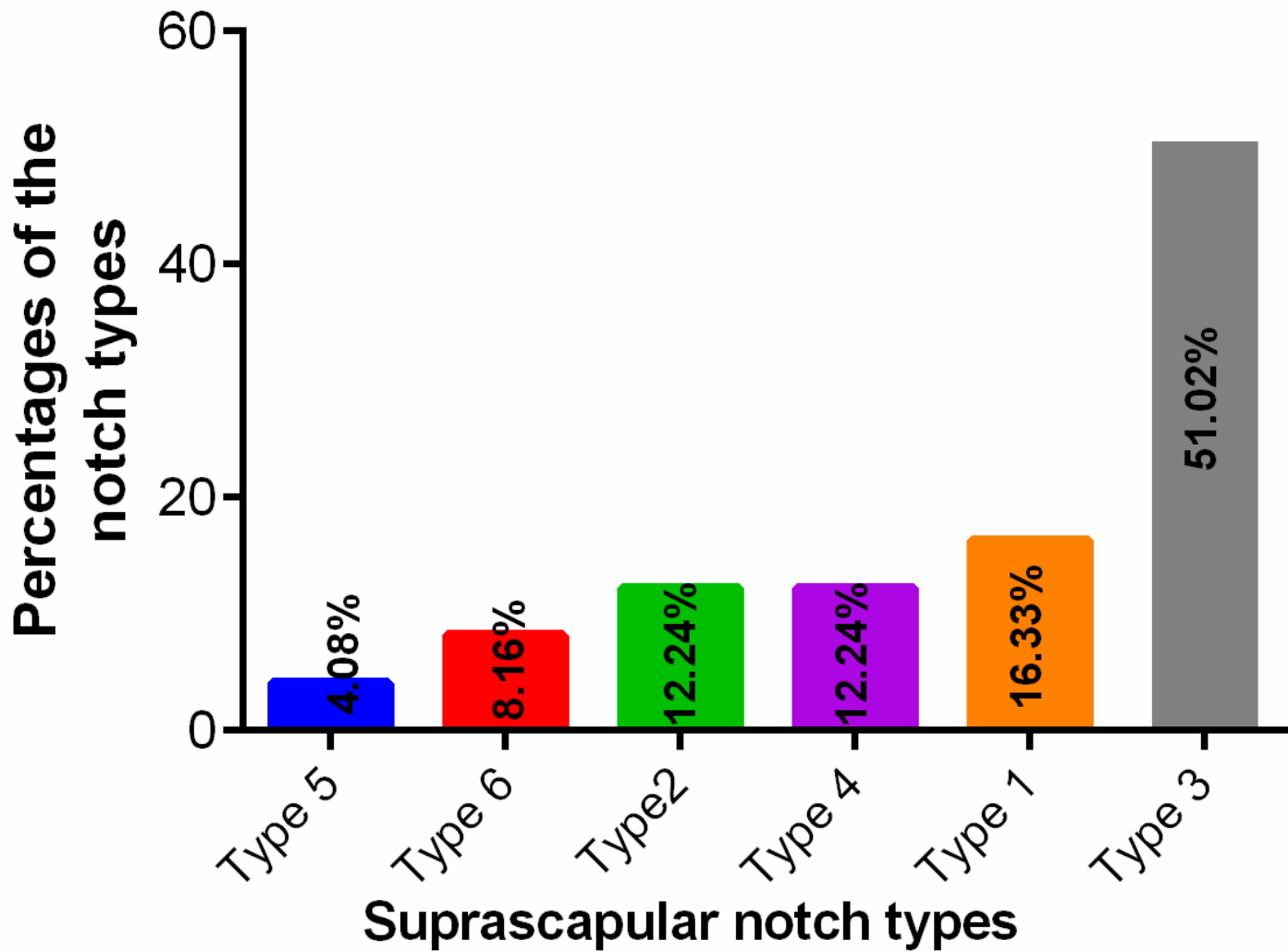
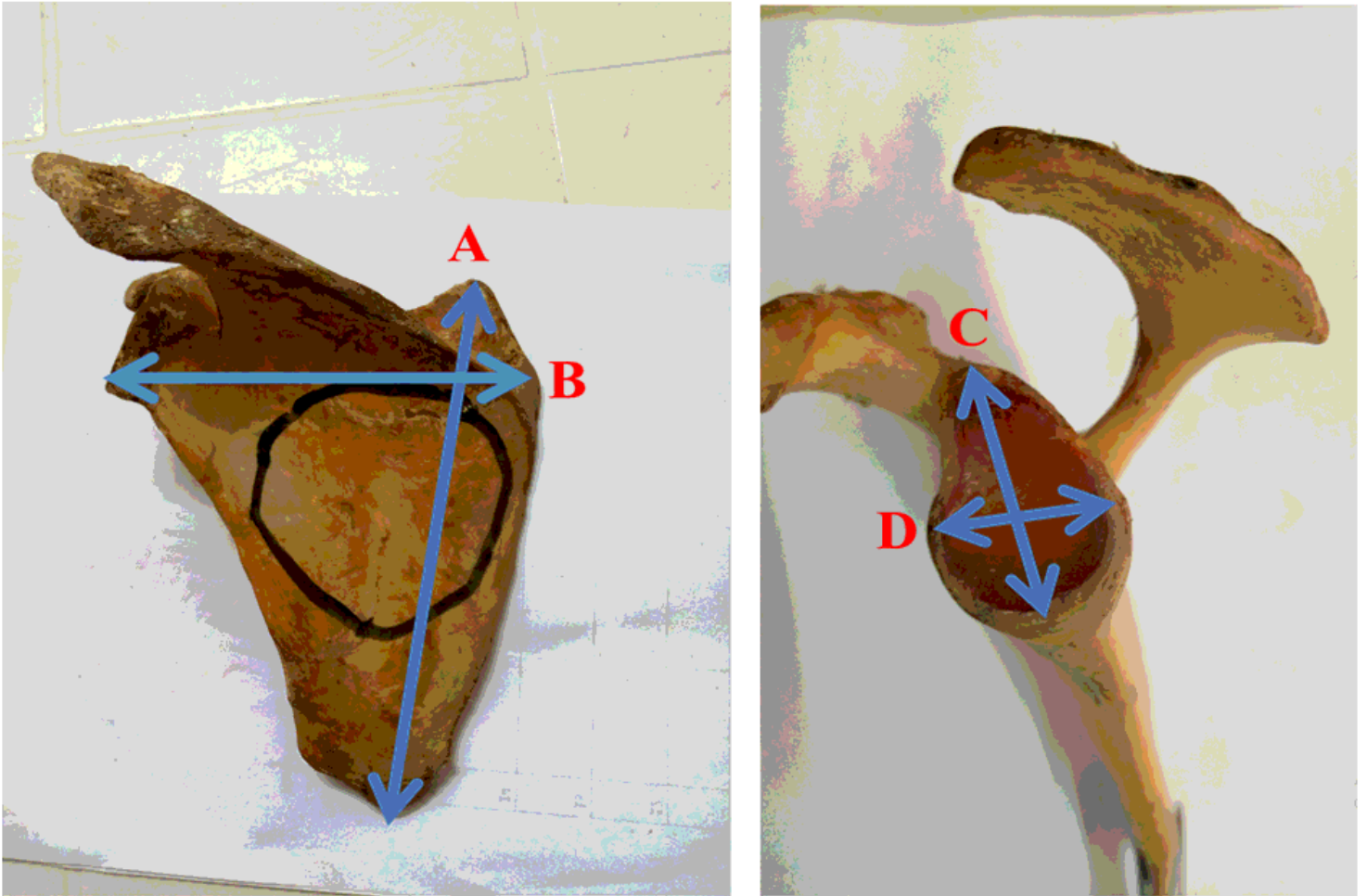


Figure 2

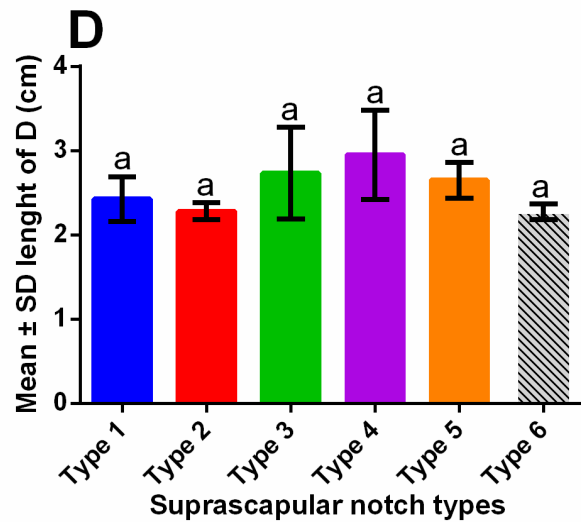
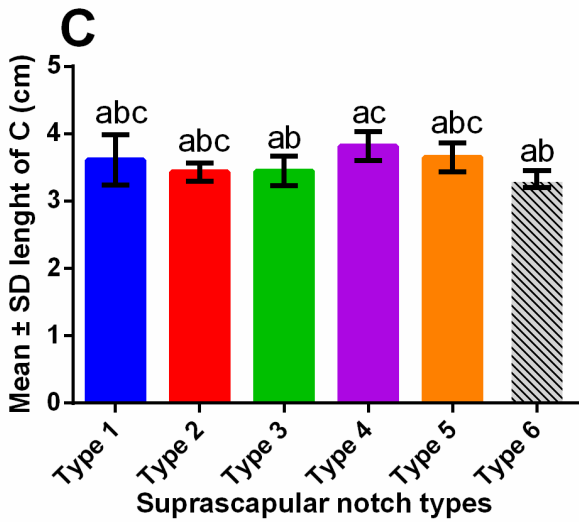
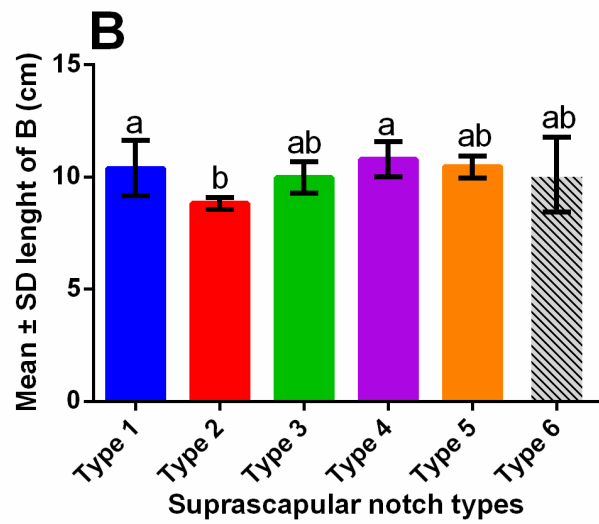
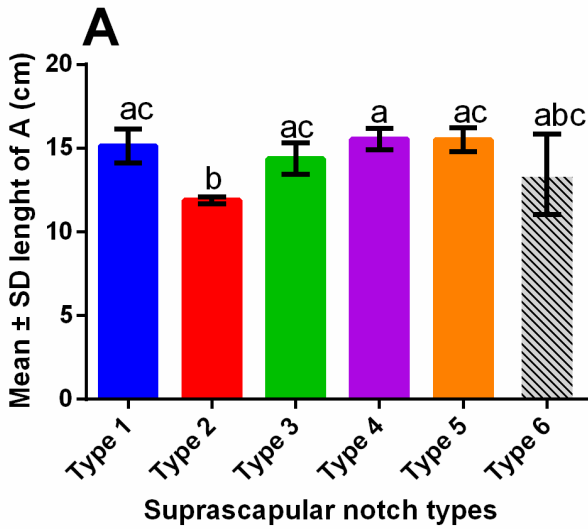
Percentage distribution of the suprascapular notch types

## OSTEOMETRIC MEASUREMENT OF SCAPULAR



**Figure 3**

Photograph showing the osteometric measurements of a left scapula. Anterior view: A= major longitudinal axis of the scapular body; B= major transversal axis of the scapular body. Lateral view: C= major longitudinal axis of the glenoid fossa; D= major transversal axis of the glenoid fossa.



**Figure 4**

Bar graphs showing the morphometric dimensions of the scapula. A= major longitudinal axis of the scapular body; B= major transversal axis of the scapular body; C= major longitudinal axis of the glenoid fossa; D= major transversal axis of the glenoid fossa. S.D = Standard deviation. a, b, and c represent relationships at  $p < 0.05$ .

## Supplementary Files

This is a list of supplementary files associated with this preprint. Click to download.

- [2Additionalfile1Multiplecomparisons.docx](#)