

# Agreement of Colposcope and Gynocular in Assessment of Cervical Lesions by Swede Score: A Randomized, Crossover Pilot Trial

Joseph Ngonzi, MD,<sup>1</sup> Francis Bajunirwe, MD, PhD,<sup>2</sup>  
Charlotte Wistrand, BSN,<sup>3,4</sup> Ronald Mayanja, MD,<sup>1</sup>  
Daniel Altman, MD, PhD,<sup>3,4</sup> Malin Thorsell, MD, PhD,<sup>3,4</sup>  
and Elisabeth Andrea Wikström Shemer, MD<sup>3</sup>

Departments of <sup>1</sup>Obstetrics and Gynecology, and <sup>2</sup>Community Health Mbarara University of Science and Technology, Mbarara, Uganda; and Departments of <sup>3</sup>Obstetrics and Gynecology, and <sup>4</sup>Clinical Sciences, Karolinska Institutet, Danderyd Hospital, Stockholm, Sweden

## ■ Abstract

**Objective.** This study aimed to determine if criterion standard colposcopy could be provided by a pocket-sized battery-driven colposcope, the Gynocular.

**Materials and Methods.** The study was a randomized, crossover, pilot clinical trial for evaluating agreement of diagnosis of cervical lesions by colposcopy using a standard colposcope and a pocket-sized battery-driven colposcope, the Gynocular, in 69 women positive for visual inspection with acetic acid. Swede scores were used at the time of colposcopy and compared with the final histological diagnosis after directed cervical biopsy. To test the level of agreement between the colposcopy and Gynocular, we calculated the percentage agreement and the  $\kappa$  statistic. We calculated the detection rates of cervical lesions of the Gynocular and a standard colposcope using biopsy results as criterion standards. All included patients also underwent a Pap smear.

**Results.** The level of agreement of Swede score between the Gynocular and colposcope was 70.1% and the  $\kappa$  statistic was 0.65 ( $p < .001$ ). Biopsy identified 4 women (6.7%) with cervical intraepithelial neoplasia 1 (CIN 1) and 1 woman

(1.7%) with CIN 2; 2 women (3.4%) had CIN 3, and 2 women had invasive cervical cancer (CIN 3+). Pap smear detected 2 women (3.1%) with CIN 1 but did not identify any high-grade cervical lesion. Cervicitis was present in 17 (27.4%) of the Pap smears and in 34 (57.6%) of the biopsies.

**Conclusions.** The study shows that in visual inspection with acetic acid–positive women, a battery-driven, pocket-sized colposcope has a significant level of agreement with stationary colposcopy in assessing cervical lesions. ■

**Key Words:** cervical cancer, colposcopy, cervical lesions, cytology, biopsy, Swede score, Gynocular

Cervical cancer is the second most common cancer in women both in incidence and mortality, with cancer deaths in women worldwide corresponding to more than 300,000 deaths in 2007 [1]. More than 90% of the cases occurred in low- and middle-income countries where access to cervical cancer screening with the Pap smear or liquid-based cytology is limited [1, 2]. Visual inspection with acetic acid (VIA) and Lugol's iodine are a suggested alternative in low-resource settings [1, 3, 4]. In industrialized countries, approximately 75% of women undergo screening, whereas in the developing world, only 5% participate in organized screening programs [1, 5]. Success in early cervical cancer detection is attributed to cytology screening and subsequent colposcopy with directed biopsies and treatment [6].

Colposcopy has the role of ruling out invasive cancer, to determine selection of sites for biopsies and eligibility

Reprint requests to: Elisabeth Andrea Wikström Shemer, MD, Department of Obstetrics and Gynecology, Department of Clinical Sciences, Karolinska Institutet, Danderyd Hospital, Stockholm, Sweden. E-mail: elisabeth@gynocular.com

The authors have declared they have no conflicts of interest.

Funding for the study was obtained from the H&M anniversary foundation (to E.A.W.S.), the Swedish Society of Medicine (to D.A.) and Gynius AB. The study was performed by independent researchers without any commercial interest in the sponsor company.

for treatment [6]. Moreover, the standard of care for patients with an abnormal screening test result is colposcopy [6]. The magnified view and strong illumination enables the examiner to visually discriminate abnormal from healthy tissues and to obtain the best representing biopsy sites for further pathological investigation [6, 7]. The colposcope provides magnification ranging from 5× to 40×; however, the magnification suggested for cervical examination is 5× to 15× [7]. Colposcopes are, however, large, heavy, and expensive stationary machines, which are confined to settings with electrical grids.

In low-resource settings, VIA and simple 2× to 4× magnification (VIAM) were developed to possibly improve VIA in detecting cervical lesions. However, VIAM was not up to the standards of a colposcope [8, 9], and in a large multicenter trial, it was concluded that low-level magnification did not improve the test performance of VIA and no benefit was found of VIAM [10]. The Gynocular was developed to provide health care personnel with a low cost, hand-held, battery-driven colposcope that enables colposcopy in any setting. This study describes a clinical pilot trial comparing the agreement of standard colposcopy and the Gynocular in assessing cervical lesions in women with positive VIA result.

## MATERIALS AND METHODS

The study was a randomized, crossover, pilot clinical trial for evaluating agreement of diagnosis of cervical lesion by colposcopy using a standard colposcope (MedGyn AL-102, MedGyn products Inc.) and a pocket-sized battery-driven colposcope, the Gynocular (Gynius AB, Stockholm, Sweden) in women positive for VIA at opportunistic screening. Two of the investigators (J.N., R.M.) screened 350 women for cervical lesions by using VIA as a screening method. Of them, 14 women (4%) had a positive VIA result; 55 VIA-positive women were detected by VIA screening before the study period. Their telephone numbers were kept, and they were re-called during the pilot study period for colposcopy. The screening was performed at tertiary care teaching hospital's cervical cancer screening clinic at the Department of Obstetrics and Gynecology, Mbarara Hospital, Uganda. In total, 69 VIA-positive women were included in the study.

The result of the VIA test was recorded as positive when there were sharp, distinct, well-defined, dense acetowhite areas, with or without raised margins, close to the squamocolumnar junction in the transformation zone. Women were asked to participate in the study as they came for their scheduled appointment for colposcopy. Inclusion criteria were women who were identified as VIA positive,

had no ongoing vaginal bleeding, had their last gynecological examination at least 1 week before, were aged between 18 and 55 years, were not pregnant, were able to understand written and oral information, and were mentally capable to provide informed consent. Exclusion criteria were that all inclusion criteria were fulfilled.

Informed consent was required before participation and duly noted in patient charts. The women were also offered to be tested for HIV. Women who chose not to participate in the study underwent standard colposcopy. All women in the study were examined by 1 of the 2 specialists in obstetrics and gynecology (J.N., R.M.). Colposcopy was performed using a standard colposcope. The Gynocular was either mounted on a camera monopod or handheld during the examination at the discretion of the gynecologist. Women were randomly allocated in a 1:1 ratio to start the examination with either colposcopy or Gynocular inspection of the cervix. All women were examined with both colposcope and the Gynocular, by 1 examiner in a crossover design, to assess the performance of agreement between the colposcope and the Gynocular. The crossover design was chosen to reduce possible observer variability [6].

Using the Swede score, each of 5 colposcopic variables (acetowhiteness, margins plus surface, vessel pattern, lesion size, and iodine staining) was given a score of 0, 1, or 2 points [11, 12]. The examination was performed in a standard lithotomy position in a gynecological chair using a self-holding speculum. The examination started with inspection of cervical vessel patterns with colposcope or Gynocular according to randomization. Then, a Pap smear was taken, and the cervix was swabbed with 4% acetic acid for 1 minute, followed by an examination by colposcope or Gynocular rendered by randomization. The examiner scored the cervix for the first 4 Swede score variables (acetowhiteness, margins plus surface, vessel pattern, and lesion size). After each examination, the 4 Swede score variables were given by the examiner and recorded by the study coordinator. The examiner then switched instruments and examined the cervix again and recorded the new 4 Swede score variables. Subsequently, the cervix was stained with 5% Lugol's iodine solution, and the examiner scored the Swede score's fifth variable (iodine staining) with both instruments according to the initial randomization. The described study design was chosen to reduce possible examiner bias. The examination was finalized with one or more biopsy specimens taken from areas of suspected cervical lesions. Punch biopsies of the cervix were performed in all participants with Swede score greater than 0 ( $n = 62$ ).

The specimens were analyzed at the histopathology laboratory of Multisystem Laboratories, Kampala, Uganda. The final diagnosis was the histopathology result and reported using the cervical intraepithelial neoplasia (CIN) system or other histopathological diagnosis in case of such finding. Women with lesions grade CIN 2 or higher underwent a loop electrical excision procedure. Women with CIN 1 lesions were given the choice of being treated directly or a follow-up appointment after 6 months. Women with invasive cancers were referred for treatment by surgery or radiotherapy.

The study was approved by the local ethics committees of Mbarara University of Science and Technology Institutional Review Committee (Dnr MUIRC 1/7) the Uganda National Council of Science and Technology as well as the Stockholm Regional Ethical Review Board.

### The Gynocular

The Gynocular is a pocket-size monocular colposcope with 5× to 12× magnification, LED illumination, green filter, and rechargeable battery and can be mounted on a camera tripod (see Figure 1 and Table 1). Optics, resolution, and illumination are comparable with a colposcope (see Table 2). The Gynocular is approved as an investigational product by the Swedish National Drug Authority as a noninvasive medical diagnostic class I tool. The Gynocular has been developed by Gynius AB, Stockholm, Sweden.

**Statistical Analysis.** Data were entered into MS Excel and exported to Stata version 11 (College Station, TX) for analysis. The baseline patient characteristics were summarized using means and frequencies (see Table 2). To test the level of agreement between the colposcopy and Gynocular, we calculated the percentage agreement



**Figure 1.** The Gynocular.

**Table 1. Technical Characteristics of the Gynocular and the Colposcope**

	Gynocular			Colposcope		
	300 mm			275 mm		
Focal distance, (mm)						
Magnification,	5×	8×	12×	4.3×	7×	11×
Field of view, mm	40	30	20	50	32	21
Resolution, lines per mm	25	40	60	30	40	42
Light source	LED			Halogen bulb		
Green filter	Yes			Yes		
Weight, g	420			8,000		
Energy source	Rechargeable battery			Electrical grid		

and the  $\kappa$  statistic (see Figure 2). A  $\kappa$  statistic greater than 0.75 indicates excellent agreement beyond that explained by chance alone, and  $\kappa$  between 0.40 and 0.75 indicates intermediate to good agreement [13]. Lesions

**Table 2. Patient Baseline Characteristics and Number of Lesions**

Patient characteristic	
Age, mean (range), y	34.8 (19–56)
HIV status, n (%)	
Negative	33 (49.3)
Positive	29 (43.3)
Unknown	5 (7.4)
No. abortions, n (%)	
None	48 (71.6)
1	7 (10.4)
2	7 (10.4)
3	1 (1.5)
4	1 (1.5)
Missing	3 (4.6)
Parity, n (%)	
0	7 (10.5)
1	6 (8.9)
2	5 (7.5)
3	8 (11.9)
4	14 (20.9)
5	6 (8.9)
6	4 (5.9)
7	10 (14.9)
>8	4 (5.8)
Missing	3 (4.4)
Cervicitis on Pap smear, n (%)	
Present	17 (27.4)
Absent	45 (72.6)
Cervicitis on biopsy, n (%)	
Present	34 (57.6)
Absent	25 (42.4)
Lesion on Pap smear, n (%)	
CIN 0	57 (96.9)
CIN 1	2 (3.1)
CIN 2	0 (0)
CIN 3	0 (0)
Lesion on biopsy, n (%)	
CIN 0	52 (84.7)
CIN 1	4 (6.7)
CIN 2	1 (1.7)
CIN 3	2 (3.4)
CIN 3+	2 (3.4)

CIN indicates cervical intraepithelial neoplasia.

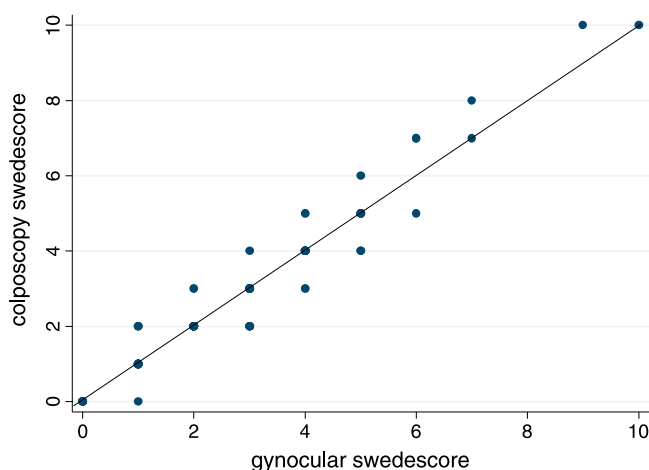
seen by the Gynocular and the colposcope were classified using Swede scores with the methodology as described by Strander et al. [11]. Swede scores of 5 or greater were considered abnormal. We calculated detection rates of CIN 1, CIN 2, CIN 3, CIN 3+, and cervicitis and compared the detection rate with the obtained Swede score (see Table 3) because the number of cases were too small to calculate sensitivity or specificity.

## RESULTS

A total of 69 VIA-positive women were included in the study. Baseline characteristics are shown in Table 2. We found that 29 women (43.3%) were HIV positive. Most women never had an abortion (48, 71.6%), and parity was high. Cervicitis was present in 17 Pap smears (27.4%) and in 34 biopsies (57.6%). Pap smear detected 2 women (3.1%) with CIN 1 but did not identify any high-grade cervical lesion (see Table 2). There was no correlation between HIV-positive result and biopsy-confirmed cervicitis ( $\chi^2$  test of association,  $p = 0.7$ ).

Biopsy identified 4 women (6.7%) with CIN 1 and 1 woman (1.7%) woman with CIN 2; 2 women had CIN 3 (3.4%), and 2 women had invasive cervical cancer (CIN 3+) (see Table 2).

The level of agreement of Swede score between the Gynocular and colposcope was 70.1%, and the  $\kappa$  statistic was 0.65 ( $p < .001$ ), indicating that the level of agreement observed between the 2 colposcopes was beyond chance



**Figure 2.** Agreement between gynocular and colposcope ( $n = 67$ ). Visual representation of the agreement between the colposcope and gynocular. The dots on the line show scores where colposcopy and gynocular have perfect agreement. The points off the line, both above and below the line, are measurements where the 2 measures do not agree, and 1 dot may represent more than 1 measurement.

**Table 3. The Swede Scores for Women With CIN 1 or Higher Grade**

CIN classification	<i>n</i>	Swede score
CIN 1	3	2
CIN 1	1	5
CIN 2	1	7
CIN 3	2	5
CIN 3+	1	7
CIN 3+	1	9

CIN indicates cervical intraepithelial neoplasia.

alone (see Figure 1). A cross tabulation of Swede scores (data not shown) on the colposcope versus Gynocular showed perfect agreement in 47 of the 67 measurements (70.1% agreement). In 11 cases (16.5%), the Gynocular scored lower than the colposcope, and the opposite happened in 9 cases (13.4%), but these differences were not statistically significant.

All cases of CIN 2 to 3+ had a Swede score of greater than 5, with no difference using the Gynocular or the colposcope. There was only 1 case of CIN 2 and had a Swede score of 7. There were 2 cases of CIN 3, and each of them had a Swede score of 5. There were 2 cases of CIN 3+, and they had Swede scores of 7 and 9 (see Table 3).

## DISCUSSION

This prospective clinical study compared the assessment of cervical lesions by a pocket-sized colposcope with a standard colposcope to determine if criterion standard colposcopy could be provided by the pocket-sized colposcope. Moreover, this is the first time Swede score has been used to evaluate cervical lesions in women with positive VIA result in a low-resource setting. The main findings were that there was a significant level of agreement of Swede score between the Gynocular and the colposcope and that the Gynocular and the colposcope to the same extent detected high-grade cervical lesions in VIA-positive women.

The limitation of the study that is a study on investigational minicolposcope that has not been clinically tested before; thus, we have no other studies to compare our results with. Another limitation is that multiple biopsies were not performed as to reduce the risk of bleeding in patients from a low-resource setting. However, a Pap smear was also performed in all patients, as an additional detection method of cervical lesions.

The Swede score system was chosen to investigate the performance of the Gynocular compared with a standard colposcope because the Swede score reliably detected

high-grade lesions when a trained colposcopist examined women who were referred for colposcopic examination owing to atypical cytology, abnormal bleeding, or visualized suspected neoplasia [11, 12, 14]. Furthermore, a low ( $\leq 4$ ) Swede score indicates that a biopsy is not needed [11, 12, 14]. Thus, a Swede score between 5 and 7 should lead to directed biopsies to exclude CIN 2+ [11, 12, 14].

Our study population consisted entirely of VIA-positive women. In recent meta-analysis of VIA, the authors identified 57 studies and chose 26 of these for the primary analysis. In these, histological examination was performed on all women (to eliminate verification bias), and the results showed 80% sensitivity and 92% specificity for VIA [15]. Thus, to further reduce the risk of verification bias, we performed biopsies on all women with Swede score of 0 or greater and took a Pap smear. To our surprise, of the 69 VIA-positive women, only 5 of them had a high-grade cervical lesion. It is possible, if multiple biopsy specimens were taken, more cases of high-grade lesion might have been detected. Pap smear detected none of the cervical lesions CIN 1 to 3+, and histological diagnosis showed cervicitis in 57.6% of the VIA-positive women. Similar findings of high rates of cervicitis in VIA-positive women verified by biopsy were shown by Davis-Dao et al. [16] in a low-resource setting in El Salvador and found to influence the results of both VIA and colposcopy. However, our findings might implicate the need of larger studies evaluating the sensitivity of Pap smear and colposcopy in low-resource settings.

Swede score has been suggested to possibly have a valuable use in disease prevention among resource-poor settings where cytological screening is absent [12]. Our pilot data show that Swede score may be a useful method to distinguish which VIA-positive women would benefit from a biopsy and/or treatment. This needs, however, to be confirmed in larger clinical trials where VIA-positive women should be investigated by colposcopy using Swede score, HPV DNA testing, liquid-based cytology, and biopsy when Swede score cuts of greater than 5 [15].

In this study, 2 expert investigators performed all examinations, which positively influenced the internal validity of our results, yet the generalizability remains undetermined. However, given that the technical specifications of the minicolposcope is equal or superior to stationary colposcopes, we do not believe that the device would negatively influence detection rates of cervical lesions when used in combination with acetic acid and

iodine solution. Specificity and sensitivity of colposcopic examinations, like most diagnostic procedures, is probably more closely related to colposcopy experience in general [6, 7].

In many regional and national health care settings, accesses to colposcopy is limited to specialized clinics and shared by a number of doctors, which limits their experience with performing colposcopy [7]. This may result in prolonged time-to-diagnosis because patients must wait for appointments and also additional costs to the patients and health care system because the patient needs to be brought to a stationary colposcope [17, 18]. It is common that the patient has to wait for weeks for a scheduled appointment, resulting in increased anxiety [19]. Thus a low-cost, portable colposcope, which does not require an electric grid, has many advantages in industrialized and developing countries alike. The even further simplified VIAM prototype had lower sensitivity rates for cervical lesions in women with abnormal cytological findings as compared with the colposcope [8, 9].

## CONCLUSIONS

The present study shows that in VIA-positive women, a portable, battery-driven, pocket-sized colposcope, which does not require an electric grid, shows a significant level of agreement with stationary colposcopy in assessing cervical lesions.

## REFERENCES

1. World Health Organization Progress reports on technical and health matters. Provisional agenda item 12.21 A 60/28. 2007.
2. Garcia M, Jemal A, Ward EM, Center MM, Hao Y, Siegel RI, et al. *Global Cancer Facts and Figures 2007*. American Cancer Society; 2007.
3. Basu PS, Sankaranarayanan R, Mandal R, Roy C, Das P, Choudhury D, et al. Visual inspection with acetic acid and cytology in the early detection of cervical neoplasia in Kolkata, India. *Int J Gynecol Cancer* 2003;13:626–32.
4. Jeronimo J, Morales O, Horna J, Pariona J, Manrique J, Rubiños J, et al. Visual inspection with acetic acid for cervical cancer screening outside of low-resource settings. *Rev Panam Salud Publica* 2005;17:1–5.
5. American Cancer Society. Cancer facts and figures 2010. Available at: [http://www5.cancer.org/downloads/STT/Cancer\\_Facts\\_and\\_Figures\\_2010.pdf](http://www5.cancer.org/downloads/STT/Cancer_Facts_and_Figures_2010.pdf). Accessed February 21, 2011.
6. Cox JT. More questions about the accuracy of colposcopy: what does that mean for cervical cancer prevention?. *Obstet Gynecol* 2008;111:1266–7.
7. Sellors JW, Sankaranarayanan R. *Colposcopy and Treatment of Cervical Intraepithelial Neoplasia: A Beginners' Manual*. Lyon, France: IARC Press; 2003:1–138.

8. Sellors JW, Winkler JL, Kreysar DF. Illumination, optics, and clinical performance of a hand-held magnified visual inspection device (AviScope): a comparison with colposcopy. *J Acquir Immune Defic Syndr* 2004;37(suppl 3):S160–6.
9. Winkler JL, Tsu VD, Bishop A, Scott R, Sellors JW. Confirmation of cervical neoplasia using a hand-held, lighted magnification device. *Int J Gynaecol Obstet* 2003;81:35–40.
10. Sankaranarayanan R, Shastri SS, Basu P, Mahé C, Mandal R, Amin G, et al. The role of low-level magnification in visual inspection with acetic acid for the early detection of cervical neoplasia. *Cancer Detect Prev* 2004;28:345–51.
11. Strander B, Ellström-Andersson A, Franzén S, Milsom I, Rådberg T. The performance of a new scoring system for colposcopy in detecting high-grade dysplasia in the uterine cervix. *Acta Obstet Gynecol Scand* 2005;84:1013–7.
12. Bowring J, Strander B, Young M, Evans H, Walker P. The Swede score: evaluation of a scoring system designed to improve the predictive value of colposcopy. *J Lower Gen Tract Dis* 2010;14:301–5.
13. Landis JR, Koch GG. The measurement of observer agreement for categorical data. *Biometrics* 1977;33:159–74.
14. Kärrberg C, Ryd W, Strander B, Brännström M, Rådberg T. Histological diagnosis and evaluation of the Swede score colposcopic system in a large cohort of pregnant women with atypical cervical cytology or cervical malignancy signs. *Acta Obstet Gynecol Scand* 2012;91:952–8.
15. Sauvaget C, Fayette JM, Muwonge R, Wesley R, Sankaranarayanan R. Accuracy of visual inspection with acetic acid for cervical cancer screening. *Int J Gynaecol Obstet* 2011; 113:14–24.
16. Davis-Dao CA, Cremer M, Felix J, Cortessis VK. Effect of cervicitis on visual inspection with acetic acid. *J Lower Gen Tract Dis* 2008;12:282–6.
17. Brown ML, Riley GF, Schussler N, Etzioni R. Estimating health care costs related to cancer treatment from SEER-Medicare Data. *Med Care* 2002;40:104–17.
18. Shireman TI, Tsevat J, Goldie SJ. Time costs associated with cervical cancer screening. *Int J Technol Assess Health Care* 2001;17:146–52.
19. Swancutt DR, Greenfield SM, Luesley DM, Wilson S. Women's experience of colposcopy: a qualitative investigation. *BMC Womens Health* 2011;11:11.