


## The liver in HIV in Africa

Shevelev Artur

### Related papers

[Download a PDF Pack](#) of the best related papers 



[Consensus conference on chronic viral hepatitis and HIV infection: updated Spanish recommendations](#)  
pere luz

[The pathogenesis of liver disease in the setting of HIV-hepatitis B virus coinfection](#)

David M Iser

[Hepatotoxicity and effectiveness of a Nevirapine-based antiretroviral therapy in HIV-infected patients](#)

Henri GWET

# The liver in HIV in Africa

Jordan J Feld\*, Ponsiano Ocama and Allan Ronald

Infectious Disease Clinic, Department of Medicine, Mulago Hospital, Kampala Uganda

\*Corresponding author: Tel: +1 301 496 1665; Fax: 301 402 0491; E-mail: feldj@niddk.nih.gov

As access to antiretroviral therapy improves across the African continent, liver disease is emerging as an important cause of morbidity and mortality among HIV-infected individuals. Although coinfection with hepatitis B virus (HBV) and hepatitis C virus (HCV), along with highly active antiretroviral therapy (HAART)-induced hepatotoxicity appear to be the major causes of

liver disease in this population, other diseases endemic to Africa with hepatic manifestations are influenced by HIV infection as well. In this review we present the available data on liver disease in HIV-infected populations in Africa and discuss relevant data from the rest of the world. In addition, we highlight important areas for further study.

## Introduction

With the improved survival among HIV-infected individuals on highly active antiretroviral therapy (HAART), liver disease has emerged as an important cause of both morbidity and mortality in this group of patients. Drug-induced hepatotoxicity along with chronic hepatitis B and C coinfection represent the major causes of liver disease in HIV-infected populations in Europe and North America. The often-limited financial and technological resources in most African countries place significant constraints on the ability to investigate and manage these common problems. In addition, many diseases endemic to Africa have hepatic manifestations, some of which are greatly impacted upon by HIV coinfection. Consequently, as widespread use of HAART is introduced across the African continent, a greater understanding of the burden of liver disease and the challenges that it presents will be necessary to properly care for HIV-infected individuals (Table 1).

So far, little is known about liver disease in HIV in Africa. In this review, we present what data are available and extrapolate from relevant data from the rest of the world. With many questions unanswered, we also propose avenues for further research.

## HBV/HIV coinfection

Hepatitis B virus (HBV) is the most common cause of chronic liver disease worldwide, with over 400 million people persistently infected [1]. HBV is endemic throughout sub-Saharan Africa, with prevalence rates for hepatitis B surface antigen (HBsAg) positivity ranging from 5–20% (Figure 1, Table 2) [2]. In addition, up to 80% of all individuals have circulating antibodies against hepatitis B core antigen immunoglobulin

G (HBe-IgG), which indicates exposure to HBV infection [3]. Given the HIV epidemic, there are a large number of HIV/HBV-coinfected people.

Because of the important role played by the host immune response in control and clearance of HBV, HIV has significant impact on the course of disease. Although no data have been reported from Africa in HIV-infected individuals, hepatitis B e antigen (HBeAg) and HBsAg clearance rates are lower and liver-related mortality is higher than in HBV-monoinfected patients [4–6]. In addition, HIV infection is associated with reactivation of HBV (reappearance of HBeAg or, rarely, HBsAg) and higher levels of circulating HBV DNA [7–9]. Lower alanine aminotransferase (ALT) levels are noted in coinfecting patients, probably reflecting a decreased immune response and possibly accounting for the slower response to anti-HBV therapy [7]. An emerging issue is the role of HBV genotype in disease outcome. Recent studies have shown that genotype E accounts for the vast majority of infections in West Africa, with a mix of genotype D and the Asian/African variant of genotype A (Aa) accounting for the remainder [10,11]. Genotype E is essentially not found outside of Africa, including in African-American populations, many of whom are of West-African origin, which suggests that it is probably a recently evolved genotype [11]. The African variant of genotype A is associated with younger HBeAg seroconversion and lower HBV DNA levels, but, aside from this, very little is known about the role of genotype in disease progression and treatment response with or without HIV coinfection in Africa [12].

Given the high prevalence of chronic HBV, it was initially assumed that most transmission occurred

**Table 1.** Differential diagnosis of liver disease in HIV+ individuals in Africa

	Comments
Viral hepatitis	
Hepatitis B	Early horizontal transmission. Reactivation with immunosuppression and/or immune reconstitution. ARVs with HBV and HIV activity – if change ARVs, must consider HBV resistance. Screen for hepatocellular carcinoma.
Hepatitis C	Rising prevalence, especially North Africa. ? Nosocomial transmission. Genotype 4 but ? changing epidemiology. Increased risk for ARV hepatotoxicity.
Delta hepatitis	Complicates HBV.
Acute hepatitis A	Probably unaffected by HIV coinfection.
Acute hepatitis E	Probably unaffected by HIV coinfection.
Hepatitis G – GBV	May slow HIV progression.
Drug hepatotoxicity	
ARVs	Baseline liver enzymes + HBsAg in all. If resources limited, re-check only if symptoms.
NNRTIs	Nevirapine hypersensitivity reaction severe; not a class effect; drug interactions.
PIs	Ritonovir most common, safe at low dose.
NRTIs	Lactic acidosis syndrome – mitochondrial toxic. High index of suspicion – d4T, ddl, AZT*
Anti-tuberculous therapy	
Rifampin	Important drug interactions especially NNRTIs.
INH	Increase with age, asymptomatic enzyme rises probably not important.
Other	Consider sulpha, anti-fungals.
Leishmaniasis	Splenomegaly, pancytopenia; diagnose on BM. Miltefosine treatment if available.
Mycobacterial disease	MAI appears to be rare; no prophylaxis. TB common – drug interactions important.
Schistosomiasis	May have portal hypertension with normal liver tests; treat if suspected.
Liver abscess (amebic)	After metronidazole, use luminal agent.
Liver mass	Consider Kaposi's, NHL or HCC.
HIV cholangiopathy	Occurs with CD4 <sup>+</sup> T cells <200; diagnose on US. Consider UDCA if severe cholestasis.

\*Toxicity is much less common for zidovudine (AZT) than for stavudine (d4T) or didanosine (ddl). ARVs, antiretrovirals; BM, bone marrow; HCC, hepatocellular carcinoma; INH, isoniazid; MAI, mycobacterium avium intracellulare; NHL, non-hodgkin's lymphoma; TB, tuberculosis; UDCA, ursodeoxycholic acid; US, ultrasound.

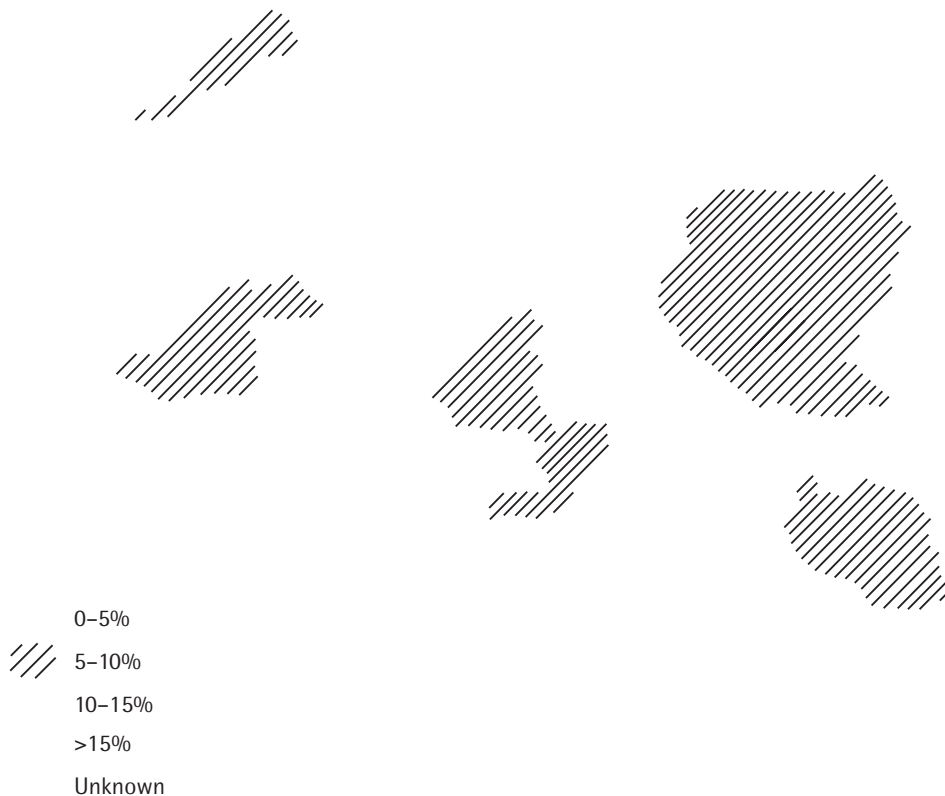vertically (that is, from mother to child). However, data suggest that many young children contract HBV horizontally from other children and/or family members [13]. In a study from southern Tanzania, 21% of infants born to women without HBV infection were HBsAg<sup>+</sup> by 18 months of age [14]. Intrafamilial spread appears to be the source of horizontal transmission, but the precise mechanism remains unclear despite its important public health implications [15]. HIV coinfection may increase rates of transmission further as a result of higher levels of HBV viraemia and potentially an increased rate of evolution to chronicity in those exposed.

Unfortunately, nosocomial HBV transmission from contaminated equipment and blood transfusions remains an important problem [16]. Health-care workers are at risk for occupational exposure because safe equipment is lacking and compliance with risk-reducing behaviours is often poor [17]. Consequently, all health-care professionals and hospital staff should be vaccinated for HBV. In most countries, blood is

screened for HBsAg; however, the techniques that are used vary widely. A study from Ghana showed that using the cheaper particle agglutination or dipstick tests, 46% and 29% of viraemic patients were missed, respectively, whereas enzyme immunoassay (EIA) identified 97% of infectious donors [18]. They found only 0.5% of HBsAg-negative, anti-HBc-positive donors were viraemic, suggesting that the additional cost of anti-HBc testing is not warranted and the focus should remain on ensuring widespread access to accurate (EIA) HBsAg testing before all transfusions.

In 1992, the World Health Organization recommended the integration of the HBV vaccination into the Expanded Program of Immunization. By 2002, 126 countries had incorporated HBV into their mass infant vaccination programmes; however, the 65 excluded countries included India and much of sub-Saharan Africa (Figure 2) [19]. Hopefully, with the assistance of the Global Alliance for Vaccines and Immunization, a coalition of private and public institutions, international HBV vaccination coverage will increase.

Figure 1. HBV prevalence in Africa by country



Perhaps the most important consideration in HBV/HIV coinfection is treatment with HAART. HBV also has a reverse transcription step in its lifecycle; therefore, some nucleoside/tide analogue reverse transcriptase inhibitors (NRTIs) developed for HIV have proven effective in controlling HBV replication [1]. The majority of clinical experience has been with lamivudine, but so far no data are available from Africa. Successful HBeAg seroconversion occurs in 22–28% of HIV/HBV-coinfected patients at 1 year, similar to that seen in HBV monoinfected patients [20]. The main concern is the development of resistance. Lamivudine resistance develops more rapidly in coinfecting patients, occurring at a rate of 20% per year [21]; this is probably due to higher HBV viral loads in these patients. The emergence of lamivudine resistance is usually clinically detected with a rise in ALT and, although it only very rarely leads to symptomatic hepatitis in the

monoinfected individual, severe and even fatal rebound hepatitis has been described in coinfecting patients [22].

Tenofovir suppresses both wild-type and lamivudine-resistant HBV and is an effective HIV agent with minimal toxicity. So far, no tenofovir-resistant HBV has been identified [23]. As CD4<sup>+</sup> T-cell counts recover on HAART, flares of hepatitis have been described in HIV/HBV-coinfecting patients, likely reflecting immune reconstitution in the setting of uncontrolled viral replication [24,25].

Because of resource limitations, viral hepatitis serology is rarely performed before starting HAART. If patients are starting HAART with anti-HBV activity (containing lamivudine and/or tenofovir), HBsAg testing should be performed and is particularly important before changing the HAART regimen [22]. All HBsAg<sup>+</sup> patients who begin a lamivudine-containing HAART regimen should

**Table 2.** Hepatitis prevalence by country

Country	HBV prevalence (%)	HCV prevalence (%)
Algeria	1.6–3.6	0.19
Angola	>10	1
Benin	16	1.4
Botswana	12	0
Burkina Faso	9.3	4.9
Burundi	4.7	3.2–14
Cameroon	9.6	6.4
Central African Rep.	14	5
Chad	15	4.8
Congo	6.5	6.4
Cote D'Ivoire	8.5	1
Dem. Rep. Congo	31.7	4.3
Djibouti	?	?
Egypt	4	10–20
Eritrea	11	?
Ethiopia	11	1.4
Gabon	7–12	6.5
Gambia	15–20	3
Ghana	15	2.8–5.4
Guinea	>10	6.7–10.7
Guinea Bissau	?	?
Kenya	11.4	0.9
Lesotho	?	?
Liberia	7.6	?
Libya	4	7.9
Madagascar	20.5	1.2–3.3
Malawi	8.1–13	6.8
Mali	9–18	?
Mauritania	22	1.1
Morocco	6	1.1
Mozambique	13.2	3.2
Namibia	14	0.9
Niger	16–29.8	6.4
Nigeria	10–24	1.4–12
Rwanda	>10	17
Senegal	13–18	1.6
Sierra Leone	18.2	2
Somalia	19	0.97
South Africa	3.6–15	0.8–1.2
Sudan	7	1.5–3.2
Swaziland	14	1.5
Tanzania	4.3–6.3	1.7
Togo	>10	3.3
Tunisia	3–26.3	0.4
Uganda	10	1.2
Western Sahara	?	?
Zambia	6–12	0
Zimbabwe	25	1.6

Hepatitis B virus (HBV) prevalence refers to rates of hepatitis B surface antigen positivity. Hepatitis C virus (HCV) prevalence rates refer to anti-HCV antibody positivity at a minimum, with HCV viraemia confirmed in some studies. Methods of data acquisition and populations studied vary considerably between countries.

remain on lamivudine or start a new HBV-active agent to reduce the risk of rebound withdrawal hepatitis even if they have already developed HIV and/or HBV lamivudine resistance.

Many questions regarding HIV/HBV coinfection in Africa remain unanswered. Understanding the mechanisms of early horizontal transmission of HBV in children has important public-health and vaccination implications. Mother-to-child HIV-transmission is reduced by treating with nevirapine or zidovudine prior to delivery. In coinfecting individuals, the use of lamivudine and/or the use of tenofovir should be investigated as potential strategies to prevent both HBV and HIV vertical transmission. There is little data on combination therapy for HBV. The availability of lamivudine- and tenofovir-containing HAART regimens should provide important information about the use of dual therapy for HBV infection. Clarification of the risk factors for flares of HBV following lamivudine discontinuation is needed. A better understanding of unique African HBV genotypes is critical, as it appears to influence natural history, treatment response and risk of liver cancer. The increased risk of HAART-induced hepatotoxicity in HBV-infected patients has not been well quantified but will have important implications for laboratory monitoring in resource-limited settings.

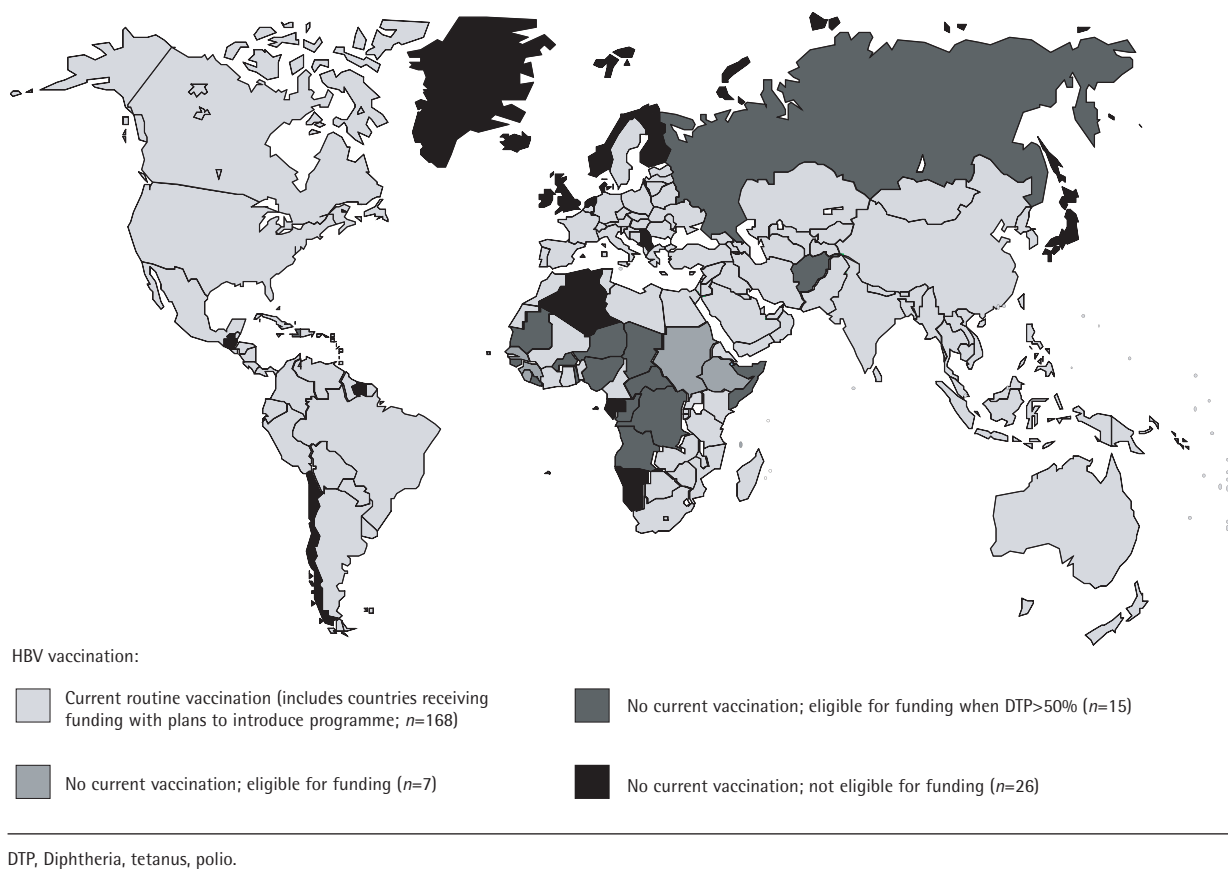
### HCV/HIV coinfection

Although less prevalent than HBV, chronic hepatitis C virus (HCV) infection is present in an estimated 170 million people or 3% of the world's population [26]. Much of the global burden of HCV disease falls in Africa, with HCV prevalence rates across the continent among the highest reported worldwide.

HCV prevalence has been estimated at 5.3% in Africa as a whole; however, it varies considerably across the continent. The highest rates of HCV infection have been found in the Nile river basin of Egypt (7.4–18%), followed by central sub-Saharan Africa (6%) and West Africa (2.4%), with the lowest rates seen in southern and eastern African countries (1.6%) (Figure 3 and Table 2) [27,28]. However, it is noteworthy that within individual countries, HCV prevalence also varies considerably [29].

Unlike in Europe and North America, studies in numerous countries in Africa have shown no correlation between HCV infection and HIV serostatus, highlighting probable different predominant modes of transmission [3,13,30–35]. North-American data suggest that HCV sexual and vertical transmission may be significantly increased from HIV/HCV-coinfecting patients [36–38]. Although potentially a very important issue, to date African sex worker cohorts have been shown to have similar rates of HCV as women attending antenatal clinics and the reported rates of vertical transmission are low [14,30,35]. The main sources of HCV transmission in Africa are yet to be

Figure 2. Status of countries using hepatitis B vaccine in their national childhood immunization schedule

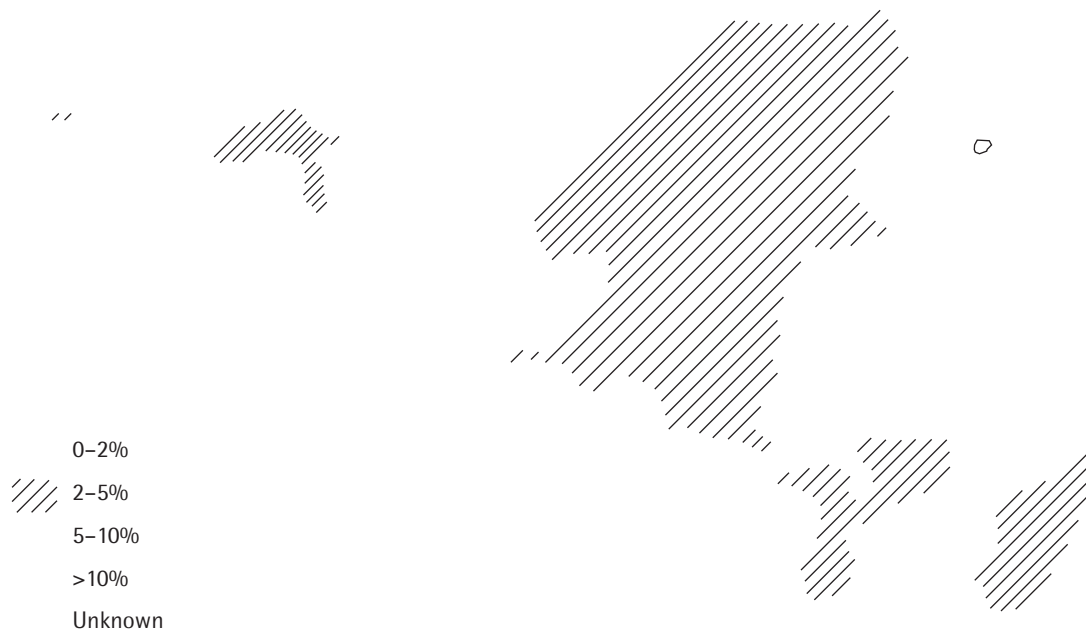

identified. Of concern, numerous studies have identified a history of parenteral medical or dental treatment and/or blood transfusion as significant risk factors for HCV acquisition [29,30,39,40]. As the prevalence of HCV increases, this may become more of a problem and urgently needs to be addressed.

No African data are available regarding the outcome of HIV/HCV coinfection; however, western data show coinfecting patients are more likely to develop chronic HCV and have more rapid progression to hepatic failure [41,42]. Although antiviral therapy has improved greatly, interferon-based therapy is prohibitively expensive in most African countries. If treatment becomes a more affordable option, HCV genotype may become an important issue. Genotype 4 is the predominant species of HCV found in Africa; however, this epidemiology may be changing. While studies from Egypt and Tanzania have found only genotype 4 infection [14,43], data from Morocco and Cameroon show a very different pattern with up to 60% genotype 1 infections [39,44]. The finding of higher prevalence of genotype 1 is concerning, given the need for longer and hence more expensive treatment.

Although specific HCV treatment is probably a long way off, HAART is rapidly spreading across the continent. As patients live longer with HIV, HCV-related liver disease may emerge as a much more significant problem. There was some initial concern that HAART may actually worsen the outcome of HCV; however, more recent reports suggest slower progression of liver disease in patients on HAART, similar to that seen in HCV mono-infection [45,46]. Hepatotoxicity with HAART appears to be more common in coinfecting patients with all classes of antiretroviral agent [47]. Perhaps antiretroviral agents with significant risk of hepatotoxicity, such as nevirapine and ritonavir, should be avoided in HCV/HIV-coinfecting patients; however, given the paucity of data, at this point HAART should certainly not be withheld from patients because of HCV coinfection. Other questions include the importance of coinfection with schistosomiasis and HCV. A better understanding of the genotypic distribution and the response to treatment of genotypes 4 and 5 will be important if treatment becomes a more feasible option in the future. Perhaps most importantly, the true modes of HCV transmission in Africa need to be identified.

Figure 3. HCV prevalence in Africa by country



## Other hepatitis viruses

Hepatitis A virus (HAV) is endemic throughout Africa and predominantly causes asymptomatic or mild disease in childhood. By early adulthood, the prevalence of markers of previous HAV infection (anti-HAV IgG) approaches 100% [48]. Consequently, with the exception of HIV-infected children, HAV/HIV coinfection is a rare event in Africa. In case series, the clinical course of HAV infection does not appear to be affected by HIV [49].

Like HAV, hepatitis E virus (HEV) is spread by fecal–oral transmission and generally causes an acute self-limited hepatitis. A very high mortality rate has been consistently reported for women who contract HEV infection in the third trimester of pregnancy (20–67%) [50]. If related to the immunosuppression of pregnancy, it is possible that HIV coinfection may also adversely affect the course of HEV infection. However,

to date very little data is available regarding the prevalence and clinical course of HEV infection among HIV-infected patients [51].

Delta hepatitis virus (HDV) is a replication-incompetent RNA virus that relies on HBV to assist with its replication cycle. HDV superinfection in HBV-infected patients can lead to fulminant hepatitis, whereas coinfection tends to modify the course of HBV only modestly. HDV prevalence rates vary greatly across Africa, with the highest rates found in the horn of Africa. Only minimal data regarding HBV/HDV/HIV coinfection are available. French investigators found that HIV counters the inhibitory effect of HDV on HBV replication but it has no apparent effect on either the level of HDV viraemia or the histological severity of liver disease [52]. Treatment of HDV infection with effective HBV agents has been disappointing. Neither long-term lamivudine monotherapy nor combination interferon therapy have achieved clinical or

virological benefit in both HIV+ and HIV- cohorts with HDV [53–57].

Hepatitis G virus (HGV), correctly known as GBV-C, shares many characteristics with HCV; however, numerous studies have demonstrated that it does not cause liver disease [58–60]. Importantly, it appears to modify the course of HIV infection, with coinfecting patients having improved survival, slower progression to AIDS and better response to HAART [61–63]. GBV-C prevalence in Africa has not been widely studied; however, it has been found to be similarly or more prevalent than HCV in Congo and Morocco [39,64]. The GBV-C/HIV-coinfection data are very provocative and have important implications for HIV-infected individuals worldwide, but particularly in Africa.

### Antiretroviral hepatotoxicity

All classes of antiretroviral agent have been associated with hepatotoxicity, but the mechanisms by which and incidence at which this occurs vary considerably between agents.

Of the non-nucleoside reverse transcriptase inhibitors (NNRTIs), nevirapine and efavirenz have been implicated to cause liver damage most frequently, including fulminant liver failure resulting in liver transplant and death [65,66]. Nevirapine most frequently causes a hypersensitivity reaction, as evidenced by the frequent coexistence of rash and fever and the common finding of high IgE levels and eosinophilia in peripheral blood and in liver biopsy specimens [67,68]. The toxicity tends to occur early (within 12 weeks of starting therapy), does not appear to be related to dose and recurs frequently and more severely with re-challenge [69]. This type of reaction has been reported more often in women and in individuals with higher CD4<sup>+</sup> T-cell counts (women with counts >250 and men with counts >400) and, consequently, it is no longer recommended for post-exposure prophylaxis [70]. It is commonly used to prevent mother-to-child transmission of HIV and has been shown to have a very safe track record with only a few episodes of mild hepatotoxicity being reported [71]. Nevirapine has also rarely been reported to cause late, dose-related liver toxicity, presumably by a direct hepatotoxic mechanism [72]. All types of hepatotoxicity seem to be more frequently observed in patients coinfecting with chronic HBV or HCV [73]. The rates of severe hepatotoxicity (aspartate aminotransferase [AST]/ALT greater than 5 times the upper limit of normal) using nevirapine and efavirenz have varied widely in different studies with reports ranging from 0–16% of treated patients [73,74]. Patients with nevirapine toxicity do not develop efavirenz hepatotoxicity with increased frequency, suggesting that these reactions are agent specific,

rather than class specific [73]. Because of the severe outcomes reported with the hypersensitivity reaction, evidence of this occurrence should prompt discontinuation of nevirapine.

Protease inhibitors (PIs) have been found to cause liver enzyme increases in between 1% and 9.5% of patients in randomized controlled trials [75]. Ritonavir has been implicated most frequently, but, importantly, the toxicity appears to be related to dose, with few or no cases of liver injury being reported in numerous trials of low-dose ritonavir [76–78]. This suggests a direct hepatotoxic effect, but little data is currently available to clarify the mechanism of PI-induced liver damage. Although HBV and HCV coinfection may increase the risk of hepatotoxicity in patients on PIs, the majority have no significant problems [75]. Although PIs may cause significant AST/ALT increases, most patients remain asymptomatic, and up to 60% in some trials have remained on the offending agent with no evidence of clinical consequence [6,75].

The NRTIs cause hepatotoxicity by a distinct mechanism of mitochondrial toxicity. By inhibition of human DNA polymerase- $\gamma$ , NRTIs cause decreased mitochondrial DNA synthesis. This reduces the capacity for oxidative phosphorylation, resulting in the accumulation of NADH, rather than NAD, favouring the conversion of pyruvate to lactate [79–81]. The lactic acidosis syndrome may develop at any time during the course of therapy [82]. Symptoms typically include malaise, nausea, vomiting, weight loss and tachypnea [83]. Although affected individuals classically have hepatomegaly, steatosis and transaminase increases, some may have hyperlactataemia alone [68]. As a result, a high index of suspicion is necessary to diagnose this potentially life-threatening syndrome, particularly in patients with normal liver enzymes. Because serum lactate levels may not be available in resource-limited settings, suspected patients should have serum electrolytes performed with calculation of the anion gap. If patients have symptoms and the anion gap is increased, the NRTI should promptly be discontinued, as the prognosis of the lactic acidosis syndrome is very poor [68]. Aside from supportive care, there is no specific management strategy and recovery is typically very slow. NRTIs should not be re-used, as recurrence rates are almost universal. All the NRTIs, including tenofovir, have been associated with this syndrome, however stavudine, didanosine and zidovudine are the most frequently implicated [82].

Although no specific data are available about the incidence of HAART hepatotoxicity from Africa, with the higher incidence of chronic viral hepatitis coinfection, it is likely to be higher than that seen in industrialized countries. In addition, with the extremely high incidence of tuberculosis, many patients on HAART



are also taking anti-tuberculous therapy concurrently, further increasing their risk of liver toxicity. Unfortunately, aside from HBV/HCV coinfection, alcohol use and older age, only higher CD4<sup>+</sup> T-cell counts with nevirapine toxicity have been identified as specific risk factors for HAART hepatotoxicity [84]. Current guidelines recommend frequent liver enzyme monitoring in patients on HAART; however, this is often difficult or impossible in resource-limited settings. It is important to note that all fatal cases of liver injury related to HAART have resulted in symptomatic disease, typically with jaundice or evidence of the lactic acidosis syndrome. The vast majority of patients with asymptomatic liver enzyme increases have continued on their HAART regimens with no evidence of adverse outcomes [75]. Clearly, a better understanding of the risk factors, the outcome and the need for liver enzyme monitoring during HAART is needed. At this point in time, baseline liver enzymes should be performed in all patients so future toxicity can be properly evaluated. If resources and/or lab facilities are limited, it is probably reasonable to monitor liver enzymes only in patients with symptomatic toxicity (evidence of hypersensitivity (with rash/fever, jaundice or right upper quadrant pain). A high index of suspicion is necessary to recognize the lactic acidosis syndrome, as symptoms are often very non-specific. Current guidelines do not recommend discontinuing/altering HAART in patients with asymptomatic liver enzyme increases, so such a strategy would be in keeping with these recommendations [75].

### HIV and mycobacterial disease

The spread of HIV has led to a marked increase in the incidence of active *Mycobacterium tuberculosis* (TB)- and *Mycobacterial avium complex* (MAC)-related disease. Disseminated TB or MAC can affect the liver, usually causing increases of ALP. MAC appears to be less common in developing countries and may be exceedingly rare or non-existent in parts of Africa [85] (A Ronald [Mulago Hospital], personal communication). The reason for this geographical variation is unknown. While TB can cause illness at any CD4<sup>+</sup> T-cell count and may be either primary infection or reactivation, MAC rarely occurs with a CD4<sup>+</sup> T-cell count >50 cells/mm<sup>3</sup>. Although effective, MAC prophylaxis is not cost-effective in resource-poor areas due to the high cost of clarithromycin and the low incidence.

Due to the high prevalence of both HIV and TB in Africa, rates of coinfection are extremely high [86]. Although hepatic involvement by TB has been well documented, the more common problem is treatment-related hepatotoxicity [87]. Because of significant potential interactions, care must be taken when

using anti-tuberculous medications and HAART simultaneously. Rifampin is a major inducer of the CYP3A4 system and consequently affects the metabolism of many antiretrovirals. The serum concentrations of both nevirapine and efavirenz are significantly reduced with rifampin co-administration. Because of additive hepatotoxicity, nevirapine should be avoided, whereas it is probably safe to increase the dose of efavirenz to 800 mg/day in patients taking rifampin [88,89]. All PI concentrations are greatly reduced by rifampin. Nucleoside analogues seem to be unaffected by rifampin. If symptomatic hepatotoxicity occurs (jaundice, nausea, vomiting and/or abdominal pain), all drugs should be stopped and sequentially re-introduced, ideally using the least hepatotoxic regimen possible. Given the fact that asymptomatic liver enzyme elevation is of questionable significance, routine screening of liver tests is probably not cost-effective in patients on TB and HAART therapy; however, baseline tests are necessary to interpret future results and all patients should be advised to stop all therapy (both HAART and TB) immediately if symptoms develop, as liver failure may be irreversible if the inciting agent is not discontinued promptly.

### HIV and leishmaniasis

Visceral leishmaniasis, caused by *Leishmania donovani* and *Leishmania infantum*, is endemic throughout the African continent and is punctuated by periodic epidemics including a devastating Sudanese outbreak in the early 1990s [90]. The clinical course ranges from asymptomatic clearance to rapidly fatal systemic illness and largely depends on the immune status of the host. HIV coinfection significantly worsens the clinical course, particularly with CD4<sup>+</sup> T-cell counts <200 cells/ml. Although precise data are lacking, estimates suggest that in Africa up to 70% of adult cases of visceral leishmaniasis occur in HIV-infected individuals and in some regions 10% of patients with AIDS present with VL as an opportunistic infection [91]. Patients classically present with fever, weight loss, massive splenomegaly, moderate hepatomegaly with or without jaundice and pancytopenia. Nodular skin lesions, lymphadenopathy and mucocutaneous ulceration may be present, particularly in Sudan. With HIV coinfection, severe gastrointestinal involvement is common with diarrhoea, malabsorption and, rarely, gastrointestinal haemorrhage. Pulmonary and central nervous system involvement have also been reported and splenomegaly may be notably absent [92–94]. As the disease progresses, neutropenia often ensues, resulting in bacterial superinfection in up to 60% of patients, most often with *Staphylococcus aureus* and

*Pseudomonas aeruginosa* [95]. Although splenic aspirate has the highest diagnostic yield, bone marrow biopsy/aspirate is generally adequate with lower risk of complications [96]. Serology is expensive and unhelpful in endemic areas because of high background rates of positivity. Although treatment with antimonial compounds is very effective for VL alone, response rates in HIV-coinfected patients have been disappointing, with 25% failing to respond and up to 80% relapsing after a course of therapy [90]. Amphotericin B is effective but expensive and toxic. Recently, miltefosine has been reported to be effective and shows initial promise in HIV-infected patients [97,98]. Even after successful treatment, parasites are often still present in splenic aspirates and prevention of reactivation relies on an intact cellular immune system; hence, long-term prophylaxis should be considered in patients with HIV. The agent of choice and ideal duration of therapy are not clear, particularly in resource-poor regions.

### HIV and schistosomiasis

The global burden of schistosomiasis is highly concentrated (85%) in sub-Saharan Africa, the region with the highest HIV prevalence worldwide [99]. The eggs of *Schistosoma mansoni* lodge in the terminal portal venules, often leading to granuloma formation. Sinusoidal compression may lead to portal hypertension. Periportal fibrosis may also be seen; however, true cirrhosis is uncommon. Consequently, liver tests may remain entirely normal despite advanced schistosomal infection. Coinfection with HIV has been demonstrated in some African countries to lead to lower egg production and fewer symptoms [100–102]. Yet, a short report from Kenyan patients with coinfection demonstrated an association between advanced hepatic fibrosis and decreased CD4<sup>+</sup> T-cell count [103]. Although anti-schistosomal therapy is equally effective in HIV-infected patients, HIV infection may impair the normal development of age-related resistance to reinfection in repeatedly exposed individuals. This may have important implications for the burden of disease [104]. When diagnostic testing is unavailable, patients with unexplained portal hypertension or persistent ALP elevation should be treated with praziquantel because significant improvement may occur even in advanced disease.

### HIV and liver abscess

HIV-related immunosuppression is a risk factor for the development of extra-intestinal amebiasis, particularly amebic liver abscess [105]. Although pyogenic liver abscesses may also occur, they do not appear to be more common with HIV infection. Fever and right

upper quadrant pain are almost universal, serum ALP is usually increased, jaundice is rare and abdominal ultrasound can confirm the diagnosis. Treatment with metronidazole is very effective and should be followed by a luminal agent such as paramomycin or iodoquinol even if stool examination is negative. Aspiration and drainage are rarely necessary [105]. Cases of tuberculous liver abscess have also been described and occasionally mimic hepatocellular carcinoma clinically [106–108].

### HIV and liver masses

Malignancy is the greatest concern when patients present with a liver mass. Although HIV itself does not seem to increase the risk for hepatocellular carcinoma (HCC), the higher rate of persistence and the more aggressive nature of hepatitis B and C in coinfecting patients may make HCC more common in these patients [109,110]. Kaposi's sarcoma and non-Hodgkin's lymphoma are well-recognized malignancies in HIV infection and are appearing with increasing frequency in many African countries [111]. In numerous cases, Kaposi's sarcoma has been identified only in the liver, highlighting the importance of a high clinical suspicion in HIV+ patients with liver masses [112,113]. Extreme care must be taken with biopsy because of the vascular nature of HCC and Kaposi's sarcoma [114].

### HIV cholangiopathy

Biliary tract disease in HIV/AIDS has been well described and is associated with severe immunosuppression with CD4<sup>+</sup> T-cell counts of <200/mm<sup>3</sup> [115,116]. Several agents have been implicated in this condition including cytomegalovirus, cryptosporidium and microsporidium [116,117]. Although there is no specific data on HIV cholangiopathy in Africa, given the severe immunosuppression seen in patients with AIDS in Africa, it is likely that the incidence of this condition is substantial. Endoscopic retrograde cholangiopancreatography is not readily available in most resource-poor countries in Africa; however, well-performed ultrasonography has been shown to be a reasonable alternative for making the diagnosis [118]. Aside from introduction of antiretroviral therapy, no specific treatment has proven effective, although if available, ursodeoxycholic acid may be of some benefit in improving cholestasis [119].

### Future directions

Hepatobiliary disease is very common in patients with HIV infection. However, in most of the resource-poor

countries of Africa there is very little information available about the aetiologies of these conditions. Some of the diagnostic investigations that are considered routine in western countries are not easily accessible in developing countries, so many African patients remain undiagnosed and untreated. There is therefore a need to perform studies in resource-constrained areas to develop cost-effective algorithms for diagnosis and possibly treatment of hepatobiliary disease in HIV-infected patients. Hopefully, effective strategies exist that do not rely entirely on the expensive technologies used in the developed world.

## Acknowledgements

There was no financial support for the preparation of this document. None of the authors has any financial conflict of interest.

## References

- Lok AS & McMahon BJ. Chronic hepatitis B. *Hepatology* 2001; **34**:1225–1241.
- Dusheiko GM, Brink BA, Conradie JD, Marimuthu T & Sher R. Regional prevalence of hepatitis B, delta, and human immunodeficiency virus infection in southern Africa: a large population survey. *American Journal of Epidemiology* 1989; **129**:138–145.
- Combe P, La Ruche G, Bonard D, Ouassa T, Faye-Kette H, Sylla-Koko F, Dabis F & the DYSCER-CI Study Group. Hepatitis B and C infections, human immunodeficiency virus and other sexually transmitted infections among women of childbearing age in Cote d'Ivoire, West Africa. *Transactions of the Royal Society of Tropical Medicine and Hygiene* 2001; **95**:493–496.
- Konopnicki D, Mocroft A, de Wit S, Antunes F, Ledergerber B, Katlama C, Zilmer K, Vella S, Kirk O, Lundgren JD & the EuroSIDA Group. Hepatitis B and HIV: prevalence, AIDS progression, response to highly active antiretroviral therapy and increased mortality in the EuroSIDA cohort. *AIDS* 2005; **19**:593–601.
- Gilson RJ, Hawkins AE, Beecham MR, Ross E, Waite J, Briggs M, McNally T, Kelly GE, Tedder RS & Weller IV. Interactions between HIV and hepatitis B virus in homosexual men: effects on the natural history of infection. *AIDS* 1997; **11**:597–606.
- Thio CL, Seaberg EC, Skolasky R Jr, Phair J, Visscher B, Munoz A, Thomas DL & the Multicenter AIDS Cohort Study. HIV-1, hepatitis B virus, and risk of liver-related mortality in the Multicenter Cohort Study (MACS). *Lancet* 2002; **360**:1921–1926.
- Vento S, Di Perri G, Garofano T, Concia E & Bassetti D. Reactivation of hepatitis B in AIDS. *Lancet* 1989; **2**:108–109.
- Lazizi Y, Grangeot-Keros L, Delfraissy JF, Boue F, Dubreuil P, Badur S & Pillot J. Reappearance of hepatitis B virus in immune patients infected with the human immunodeficiency virus type 1. *The Journal of Infectious Diseases* 1988; **158**:666–667.
- Colin JF, Cazals-Hatem D, Lioriot MA, Martinot-Peignoux M, Pham BN, Auperin A, Degott C, Benhamou JP, Erlinger S, Valla D & Marcellin P. Influence of human immunodeficiency virus infection on chronic hepatitis B in homosexual men. *Hepatology* 1999; **29**:1306–1310.
- Kramvis A, Restorp K, Norder H, Botha JF, Magnusius LO & Kew MC. Full genome analysis of hepatitis B virus genotype E strains from South-Western Africa and Madagascar reveals low genetic variability. *Journal of Medical Virology* 2005; **77**:47–52.
- Mulders MN, Venard V, Njayou M, Etorh AP, Bola Oyefolu AO, Kehinde MO, Muyembe Tamfum JJ, Nebie YK, Maiga I, Ammerlaan W, Fack F, Omilabu SA, Le Faou A & Muller CP. Low genetic diversity despite hyperendemicity of hepatitis B virus genotype E throughout West Africa. *The Journal of Infectious Diseases* 2004; **190**:400–408.
- Tanaka Y, Hasegawa I, Kato T, Orito E, Hirashima N, Acharya SK, Gish RG, Kramvis A, Kew MC, Yoshihara N, Shrestha SM, Khan M, Miyakawa Y & Mizokami M. A case-control study for differences among hepatitis B virus infections of genotypes A (subtypes Aa and Ae) and D. *Hepatology* 2004; **40**:747–755.
- Nur YA, Groen J, Elmi AM, Ott A & Osterhaus AD. Prevalence of serum antibodies against bloodborne and sexually transmitted agents in selected groups in Somalia. *Epidemiology and Infection* 2000; **124**:137–141.
- Menendez C, Sanchez-Tapias JM, Kahigwa E, Mshinda H, Costa J, Vidal J, Acosta C, Lopez-Labrador X, Olmedo E, Navia M, Tanner M, Rodes J & Alonso PL. Prevalence and mother-to-infant transmission of hepatitis viruses B, C, and E in Southern Tanzania. *Journal of Medical Virology* 1999; **58**:215–220.
- Dumpis U, Holmes EC, Mendy M, Hill A, Thursz M, Hall A, Whittle H & Karayiannis P. Transmission of hepatitis B virus infection in Gambian families revealed by phylogenetic analysis. *Journal of Hepatology* 2001; **35**:99–104.
- Yerly S, Quadri R, Negro F, Barbe KP, Cheseaux JJ, Burgisser P, Siegrist CA & Perrin L. Nosocomial outbreak of multiple bloodborne viral infections. *The Journal of Infectious Diseases* 2001; **184**:369–372.
- Ansa VO, Udoma EJ, Umoh MS & Anah MU. Occupational risk of infection by human immunodeficiency and hepatitis B viruses among health workers in south-eastern Nigeria. *East African Medical Journal* 2002; **79**:254–256.
- Allain JP, Candotti D, Soldan K, Sarkodie F, Phelps B, Giachetti C, Shyamala V, Yeboah F, Anokwa M, Owusu-Ofori S & Opare-Sem O. The risk of hepatitis B virus infection by transfusion in Kumasi, Ghana. *Blood* 2003; **101**:2419–2425.
- Andre F. Hepatitis B: a comprehensive prevention, diagnosis, and treatment program – past, present, and future. *Journal of Gastroenterology and Hepatology* 2004; **19**:1–4.
- Benhamou Y, Katlama C, Lunel F, Coutellier A, Dohin E, Hamm N, Tubiana R, Herson S, Poynard T & Opolon P. Effects of lamivudine on replication of hepatitis B virus in HIV-infected men. *Annals of Internal Medicine* 1996; **125**:705–712.
- Benhamou Y, Bochet M, Thibault V, Di Martino V, Caumes E, Bricaire F, Opolon P, Katlama C & Poynard T. Long-term incidence of hepatitis B virus resistance to lamivudine in human immunodeficiency virus-infected patients. *Hepatology* 1999; **30**:1302–1306.
- Lim SG, Wai CT, Rajnakova A, Kajiji T & Guan R. Fatal hepatitis B reactivation following discontinuation of nucleoside analogues for chronic hepatitis B. *Gut* 2002; **51**:597–599.
- Nunez M, Perez-Olmeda M, Diaz B, Rios P, Gonzalez-Lahoz J & Soriano V. Activity of tenofovir on hepatitis B virus replication in HIV-co-infected patients failing or partially responding to lamivudine. *AIDS* 2002; **16**:2352–2354.
- Carr A & Cooper DA. Restoration of immunity to chronic hepatitis B infection in HIV-infected patient on protease inhibitor. *Lancet* 1997; **349**:995–996.
- Velasco M, Moran A & Tellez MJ. Resolution of chronic hepatitis B after ritonavir treatment in an HIV-infected patient. *The New England Journal of Medicine* 1999; **340**:1765–1766.
- Memon MI & Memon MA. Hepatitis C: an epidemiological review. *Journal of Viral Hepatitis* 2002; **9**:84–100.

27. el-Sayed NM, Gomatos PJ, Rodier GR, Wierzba TF, Darwish A, Khashaba S & Arthur RR. Seroprevalence survey of Egyptian tourism workers for hepatitis B virus, hepatitis C virus, human immunodeficiency virus, and *Treponema pallidum* infections: association of hepatitis C virus infections with specific regions of Egypt. *The American Journal of Tropical Medicine and Hygiene* 1996; 55:179–184.
28. Madhava V, Burgess C & Drucker E. Epidemiology of chronic hepatitis C virus infection in sub-Saharan Africa. *The Lancet Infectious Diseases* 2002; 2:293–302.
29. Kitundu J, Msengi A, Matee M, Fataki M, Kazimoto T, Mpembeni R, Mnuhhi E & Kalokola F. Post-transfusion hepatitis C seroprevalence in Tanzanian children. *Annals of Tropical Paediatrics* 2001; 21:343–348.
30. Laurent C, Henzel D, Mulanga-Kabeya C, Maertens G, Larouze B & Delaporte E. Seroepidemiological survey of hepatitis C virus among commercial sex workers and pregnant women in Kinshasa, Democratic Republic of Congo. *International Journal of Epidemiology* 2001; 30:872–877.
31. Pawlowsky JM, Belec L, Gresenguet G, Deforges L, Bouvier M, Duval J & Dhumeaux D. High prevalence of hepatitis B, C, and E markers in young sexually active adults from the Central African Republic. *Journal of Medical Virology* 1995; 46:269–272.
32. Ahmed SD, Cuevas LE, Brabin BJ, Kazembe P, Broadhead R, Verhoeff FH & Hart CA. Seroprevalence of hepatitis B and C and HIV in Malawian pregnant women. *The Journal of Infection* 1998; 37:248–251.
33. Basaras M, Santamaria A, Sarsa M, Gutierrez E, de Olano Y & Cisterna R. Seroprevalence of hepatitis B and C, and human immunodeficiency type 1 viruses in a rural population from the Republic of Equatorial Guinea. *Transactions of the Royal Society of Tropical Medicine and Hygiene* 1999; 93:250–252.
34. Sutcliffe S, Taha TE, Kumwenda NI, Taylor E & Liomba GN. HIV-1 prevalence and herpes simplex virus 2, hepatitis C virus, and hepatitis B virus infections among male workers at a sugar estate in Malawi. *Journal of Acquired Immune Deficiency Syndromes* 2002; 31:90–97.
35. Ayele W, Nokes DJ, Abebe A, Messele T, Dejene A, Enquselassie F, Rinke de Wit TF & Fontanet AL. Higher prevalence of anti-HCV antibodies among HIV-positive compared to HIV-negative inhabitants of Addis Ababa, Ethiopia. *Journal of Medical Virology* 2002; 68:12–17.
36. Soto B, Rodrigo L, Garcia-Bengoechea M, Sanchez-Quijano A, Riestra S, Arenas JJ, Andreu J, Rodriguez M, Emparanza JJ, Torres Y, et al. Heterosexual transmission of hepatitis C virus and the possible role of coexistent human immunodeficiency virus infection in the index case. A multicentre study of 423 pairings. *J Intern Med* 1994; 236:515–519.
37. Eyster ME, Alter HJ, Aledort LM, Quan S, Hatzakis A & Goedert JJ. Heterosexual co-transmission of hepatitis C virus (HCV) and human immunodeficiency virus (HIV). *Annals of Internal Medicine* 1991; 115:764–768.
38. Yeung LT, King SM & Roberts EA. Mother-to-infant transmission of hepatitis C virus. *Hepatology* 2001; 34:223–229.
39. Cacoub P, Ohayon V, Sekkat S, Dumont B, Sbai A, Lunel F, Benslimane A, Godeau P & Archane MI. Epidemiologic and virologic study of hepatitis C virus infections in Morocco. *Gastroenterologie Clinique et Biologique* 2000; 24:169–173.
40. Candotti D, Mundy C, Kadeweile G, Nkhoma W, Bates I & Allain JP. Serological and molecular screening for viruses in blood donors from Ntcheu, Malawi: high prevalence of HIV-1 subtype C and of markers of hepatitis B and C viruses. *Journal of Medical Virology* 2001; 65:1–5.
41. Thomas DL, Astemborski J, Rai RM, Anania FA, Schaeffer M, Galai N, Nolt K, Nelson KE, Strathdee SA, Johnson L, Laeyendecker O, Boitnott J, Wilson LE & Vlahov D. The natural history of hepatitis C virus infection: host, viral, and environmental factors. *JAMA* 2000; 284:450–456.
42. Telfer P, Sabin C, Devereux H, Scott F, Dusheiko G & Lee C. The progression of HCV-associated liver disease in a cohort of haemophilic patients. *British Journal of Haematology* 1994; 87:555–561.
43. Attia MA. Prevalence of hepatitis B and C in Egypt and Africa. *Antiviral Therapy* 1998; 3:1–9.
44. Ndjomou J, Kupfer B, Kochan B, Zekeng L, Kaptue L & Matz B. Hepatitis C virus infection and genotypes among human immunodeficiency virus high-risk groups in Cameroon. *Journal of Medical Virology* 2002; 66:179–186.
45. Tural C, Fuster D, Tor J, Ojanguren I, Sirera G, Ballesteros A, Lasanta JA, Planas R, Rey-Joly C & Clotet B. Time on antiretroviral therapy is a protective factor for liver fibrosis in HIV and hepatitis C virus (HCV) co-infected patients. *Journal of Viral Hepatitis* 2003; 10:118–125.
46. Sterling RK & Sulkowski MS. Hepatitis C virus in the setting of HIV or hepatitis B virus coinfection. *Seminars in Liver Disease* 2004; 24:61–68.
47. Barbaro G, Di Lorenzo G, Asti A, Ribersani M, Belloni G, Grisorio B, Filice G & Barbarini G. Hepatocellular mitochondrial alterations in patients with chronic hepatitis C: ultrastructural and biochemical findings. *The American Journal of Gastroenterology* 1999; 94:2198–2205.
48. Aubry P, Niel L, Niyongabo T, Kerguelen S & Larouze B. Seroprevalence of hepatitis E virus in an adult urban population from Burundi. *The American Journal of Tropical Medicine and Hygiene* 1997; 57:272–273.
49. Fonquernie L, Meynard JL, Charrois A, Delamare C, Meyohas MC & Frottier J. Occurrence of acute hepatitis A in patients infected with human immunodeficiency virus. *Clinical Infectious Diseases* 2001; 32:297–299.
50. Singh S, Mohanty A, Joshi YK, Deka D, Mohanty S & Panda SK. Mother-to-child transmission of hepatitis E virus infection. *Indian Journal of Pediatrics* 2003; 70:37–39.
51. Balayan MS, Fedorova OE, Mikhailov MI, Rytick PG, Eremin VF, Danilova TI, Shevelev BI, Gorbacheva EC & Pankova GY. Antibody to hepatitis E virus in HIV-infected individuals and AIDS patients. *Journal of Viral Hepatitis* 1997; 4:279–283.
52. Pol S, Wesenfelder L, Dubois F, Roingard P, Carnot F, Driss F, Brechot C, Goudeau A & Berthelot P. Influence of human immunodeficiency virus infection on hepatitis delta virus superinfection in chronic HBsAg carriers. *Journal of Viral Hepatitis* 1994; 1:131–137.
53. Di Marco V, Giacchino R, Timitilli A, Bortolotti F, Crivellaro C, Calzia R, Iannuzzi C, Prestileo T, Vajro P, Nebbia G, Stringhi C, Rosina F, Biassoni D, Callea F, Rizzetto M & Craxi A. Long-term interferon-alpha treatment of children with chronic hepatitis delta: a multicentre study. *Journal of Viral Hepatitis* 1996; 3:123–128.
54. Lau DT, Doo E, Park Y, Kleiner DE, Schmid P, Kuhns MC & Hoofnagle JH. Lamivudine for chronic delta hepatitis. *Hepatology* 1999; 30:546–549.
55. Puoti M, Rossi S, Forleo MA, Zaltron S, Spinetti A, Putzolu V, Rodella A & Carosi G. Treatment of chronic hepatitis D with interferon alpha-2b in patients with human immunodeficiency virus infection. *Journal of Hepatology* 1998; 29:45–52.
56. Wolters LM, van Nunen AB, Honkoop P, Vossen AC, Niesters HG, Zondervan PE & de Man RA. Lamivudine-high dose interferon combination therapy for chronic hepatitis B patients co-infected with the hepatitis D virus. *Journal of Viral Hepatitis* 2000; 7:428–434.
57. Yurdaydin C, Bozkaya H, Gurel S, Tillmann HL, Aslan N, Okcu-Heper A, Erden E, Yalcin K, Iliman N, Uzunlimoglu O, Manns MP & Bozdayi AM. Famciclovir treatment of chronic delta hepatitis. *Journal of Hepatology* 2002; 37:266–271.
58. Alter HJ, Nakatsuji Y, Melpolder J, Wages J, Wesley R, Shih JW & Kim JP. The incidence of transfusion-associated hepatitis G virus infection and its relation to liver disease. *The New England Journal of Medicine* 1997; 336:747–754.

59. Di SR, Ferraro D, Bonura C, Lo PG, Lacono O, Di MV & Craxi A. Are hepatitis G virus and TT virus involved in cryptogenic chronic liver disease? *Digestive and Liver Disease* 2002; 34:53–58.
60. De Filippi F, Lampertico P, Soffredini R, Rumi MG, Lunghi G, Aroldi A, Tarantino A, Ponticelli C & Colombo M. High prevalence, low pathogenicity of hepatitis G virus in kidney transplant recipients. *Digestive and Liver Disease* 2001; 33:477–479.
61. Lefrere JJ, Roudot-Thoraval F, Morand-Joubert L, Petit JC, Lerable J, Thauvin M & Mariotti M. Carriage of GB virus C/hepatitis G virus RNA is associated with a slower immunologic, virologic, and clinical progression of human immunodeficiency virus disease in coinfecting persons. *The Journal of Infectious Diseases* 1999; 179:783–789.
62. Yeo AE, Matsumoto A, Hisada M, Shih JW, Alter HJ & Goedert JJ. Effect of hepatitis G virus infection on progression of HIV infection in patients with hemophilia. Multicenter Hemophilia Cohort Study. *Annals of Internal Medicine* 2000; 132:959–963.
63. Tillmann HL, Heiken H, Knapik-Botor A, Heringlake S, Ockenga J, Wilber JC, Goergen B, Detmer J, McMorrow M, Stoll M, Schmidt RE & Manns MP. Infection with GB virus C and reduced mortality among HIV-infected patients. *The New England Journal of Medicine* 2001; 345:715–724.
64. Liu HF, Muyembe-Tamfum JJ, Dahan K, Desmyter J & Goubau P. High prevalence of GB virus C/hepatitis G virus in Kinshasa, Democratic Republic of Congo: a phylogenetic analysis. *Journal of Medical Virology* 2000; 60:159–165.
65. Nunez M, Lana R, Mendoza JL, Martin-Carbonero L & Soriano V. Risk factors for severe hepatic injury after introduction of highly active antiretroviral therapy. *Journal of Acquired Immune Deficiency Syndromes* 2001; 27:426–431.
66. Abrescia N, D'Abbraccio M, Figoni M, Busto A, Butrico E, De Marco M & Viglietti R. Fulminant hepatic failure after the start of an efavirenz-based HAART regimen in a treatment-naive female AIDS patient without hepatitis virus co-infection. *The Journal of Antimicrobial Chemotherapy* 2002; 50:763–765.
67. Warren KJ, Boxwell DE, Kim NY & Drolet BA. Nevirapine-associated Stevens–Johnson syndrome. *Lancet* 1998; 351:567.
68. Kontorinis N & Dieterich DT. Toxicity of non-nucleoside analogue reverse transcriptase inhibitors. *Seminars in Liver Disease*. 2003; 23:173–182.
69. Centers for Disease Control and Prevention. Serious adverse events attributed to nevirapine regimens for post-exposure prophylaxis after HIV exposures-worldwide, 1997–2000. *Morbidity and Mortality Weekly Report* 2001; 49:1153–6.
70. Bersoff-Matcha SJ, Miller WC, Aberg JA, van Der Horst C, Hamrick Jr HJ, Powderly WG & Mundy LM. Sex differences in nevirapine rash. *Clinical Infectious Diseases* 2001; 32:124–129.
71. Yeni PG, Hammer SM, Carpenter CC, Cooper DA, Fischl MA, Gatell JM, Gazzard BG, Hirsch MS, Jacobsen DM, Katzenstein DA, Montaner JS, Richman DD, Saag MS, Schechter M, Schooley RT, Thompson MA, Vella S & Volberding PA. Antiretroviral treatment for adult HIV infection in 2002: updated recommendations of the International AIDS Society-USA Panel. *JAMA* 2002; 288:222–235.
72. Clarke S, Harrington P, Condon C, Kelleher D, Smith OP & Mulcahy F. Late onset hepatitis and prolonged deterioration in hepatic function associated with nevirapine therapy. *International Journal of STD and AIDS* 2000; 11:336–337.
73. Sulkowski MS, Thomas DL, Mehta SH, Chaisson RE & Moore RD. Hepatotoxicity associated with nevirapine or efavirenz-containing antiretroviral therapy: role of hepatitis C and B infections. *Hepatology* 2002; 35:182–189.
74. D'Aquila RT, Hughes MD, Johnson VA, Fischl MA, Sommadossi JP, Liou SH, Timponi J, Myers M, Basgoz N, Niu M & Hirsch MS. Nevirapine, zidovudine, and didanosine compared with zidovudine and didanosine in patients with HIV-1 infection. A randomized, double-blind, placebo-controlled trial. National Institute of Allergy and Infectious Diseases AIDS Clinical Trials Group Protocol 241 Investigators. *Annals of Internal Medicine* 1996; 124:1019–1030.
75. Sulkowski MS. Hepatotoxicity associated with antiretroviral therapy containing HIV-1 protease inhibitors. *Seminars in Liver Disease* 2003; 23:183–194.
76. Walmsley S, Bernstein B, King M, Arribas J, Beall G, Ruane P, Johnson M, Johnson D, Lalonde R, Japour A, Brun S, Sun E & the M98-863 Study Team. Lopinavir-ritonavir versus nelfinavir for the initial treatment of HIV infection. *The New England Journal of Medicine* 2002; 346:2039–2046.
77. Vora S, Michon C, Junet C, Balavoine JF, Renold-Moynier C, Yerly S & Perrin L. Switch from indinavir to ritonavir-indinavir regimen in patients treated with highly active antiretroviral therapy co-infected with hepatitis C is not associated with alteration of liver function tests. *AIDS* 2000; 14:2795–2797.
78. Wit FW, Weverling GJ, Weel J, Jurriaans S & Lange JM. Incidence of and risk factors for severe hepatotoxicity associated with antiretroviral combination therapy. *The Journal of Infectious Diseases*. 2002; 186:23–31.
79. Lewis W & Dalakas MC. Mitochondrial toxicity of antiviral drugs. *Nature Medicine* 1995; 1:417–422.
80. Brinkman K, ter Hofstede HJ, Burger DM, Smeitink JA & Koopmans PP. Adverse effects of reverse transcriptase inhibitors: mitochondrial toxicity as common pathway. *AIDS* 1998; 12:1735–1744.
81. Montessori V, Harris M & Montaner JS. Hepatotoxicity of nucleoside reverse transcriptase inhibitors. *Seminars in Liver Disease* 2003; 23:167–172.
82. Fortgang IS, Belitsos PC, Chaisson RE & Moore RD. Hepatomegaly and steatosis in HIV-infected patients receiving nucleoside analog antiretroviral therapy. *The American Journal of Gastroenterology* 1995; 90:1433–1436.
83. Lonergan JT, Behling C, Pfander H, Hassanein TI & Mathews WC. Hyperlactatemia and hepatic abnormalities in 10 human immunodeficiency virus-infected patients receiving nucleoside analogue combination regimens. *Clinical Infectious Diseases* 2000; 31:162–166.
84. Nunez M & Soriano V. Hepatotoxicity of antiretrovirals: incidence, mechanisms and management. *Drug Safety* 2005; 28:53–66.
85. Fordham von Reyn C, Arbeit RD, Tosteson AN, Ristola MA, Barber TW, Waddell R, Sox CH, Brindle RJ, Gilks CF, Rankin A, Bartholomew C, Edwards J, Falkingham JO 3rd & O'Connor GT. The international epidemiology of disseminated *Mycobacterium avium* complex infection in AIDS. *AIDS* 1996; 10:1025–1032.
86. Raviglione MC, Harries AD, Msiska R, Wilkinson D & Nunn P. Tuberculosis and HIV: current status in Africa. *AIDS* 1997; 11:115–123.
87. Amarapurkar AD & Sangle NA. Histological spectrum of liver in HIV – autopsy study. *Annals of Hepatology* 2005; 4:47–51.
88. Ribera E, Pou L, Lopez RM, Crespo M, Falco V, Ocana I, Ruiz I & Pahissa A. Pharmacokinetic interaction between nevirapine and rifampicin in HIV-infected patients with tuberculosis. *Journal of Acquired Immune Deficiency Syndromes* 2001; 28:450–453.
89. Wendland T, Furrer H, Vernazza PL, Frutiger K, Christen A, Matter L, Malinverni R & Pichler WJ. HAART in HIV-infected patients: restoration of antigen-specific CD4 T-cell responses *in vitro* is correlated with CD4 memory T-cell reconstitution, whereas improvement in delayed type hypersensitivity is related to a decrease in viraemia. *AIDS* 1999; 13:1857–1862.
90. Seaman J, Mercer AJ, Sondorp HE & Herwaldt BL. Epidemic visceral leishmaniasis in southern Sudan: treatment of severely debilitated patients under wartime

- conditions and with limited resources. *Annals of Internal Medicine* 1996; **124**:664–672.
91. Bal AM. Visceral leishmaniasis – an opportunistic infection in HIV-infected patients. *The Lancet Infectious Diseases* 2005; **5**:196–197.
  92. Laguna F, Garcia-Samaniego J, Soriano V, Valencia E, Redondo C, Alonso MJ & Gonzalez-Lahoz JM. Gastrointestinal leishmaniasis in human immunodeficiency virus-infected patients: report of five cases and review. *Clinical Infectious Diseases* 1994; **19**:48–53.
  93. Pulido F, Rubio R & Costa JR. Visceral leishmaniasis as a cause of diarrhoea in HIV-infected patients *AIDS* 1995; **9**:661–662.
  94. Peters BS, Fish D, Golden R, Evans DA, Bryceson AD & Pinching AJ. Visceral leishmaniasis in HIV infection and AIDS: clinical features and response to therapy. *The Quarterly Journal of Medicine* 1990; **77**:1101–1111.
  95. Andrade TM, Carvalho EM & Rocha H. Bacterial infections in patients with visceral leishmaniasis. *The Journal of Infectious Diseases* 1990; **162**:1354–1359.
  96. Pearson RD & Sousa AQ. Clinical spectrum of Leishmaniasis. *Clinical Infectious Diseases* 1996; **22**:1–13.
  97. Sundar S, Jha TK, Thakur CP, Engel J, Sindermann H, Fischer C, Junge K, Bryceson A & Berman J. Oral miltefosine for Indian visceral leishmaniasis. *The New England Journal of Medicine* 2002; **347**:1739–1746.
  98. Sindermann H, Engel KR, Fischer C & Bommer W. Oral miltefosine for leishmaniasis in immunocompromised patients: compassionate use in 39 patients with HIV infection. *Clinical Infectious Diseases* 2004; **39**:1520–1523.
  99. Utzinger J, Bergquist R, Shu-Hua X, Singer BH & Tanner M. Sustainable schistosomiasis control – the way forward. *Lancet* 2003; **362**:1932–1934.
  100. Fontanet AL, Woldemichael T, Sahlu T, van Dam GJ, Messele T, Rinke de Wit T, Masho W, Yeneneh H, Coutinho RA & van Lieshout L. Epidemiology of HIV and Schistosoma mansoni infections among sugar-estate residents in Ethiopia. *Annals of Tropical Medicine and Parasitology* 2000; **94**:145–155.
  101. N'Zoukoudi-N'Doundou MY, Dirat I, Akouala JJ, Penchenier L, Makuwa M & Rey JL. Bilharziasis and human immunodeficiency virus infection in Congo. *Medecine Tropicale* 1995; **55**:249–251.
  102. Mwanakasale V, Vounatsou P, Sukwa TY, Ziba M, Ernest A & Tanner M. Interactions between Schistosoma haematobium and human immunodeficiency virus type 1: the effects of coinfection on treatment outcomes in rural Zambia. *The American Journal of Tropical Medicine and Hygiene* 2003; **69**:420–428.
  103. Mwinzi PN, Karanja DM, Kareko I, Magak PW, Orago AS, Colley DG & Secor WE. Short report: Evaluation of hepatic fibrosis in persons co-infected with Schistosoma mansoni and human immunodeficiency virus 1. *The American Journal of Tropical Medicine and Hygiene* 2004; **71**:783–786.
  104. Karanja DM, Hightower AW, Colley DG, Mwinzi PN, Galil K, Andove J & Secor WE. Resistance to reinfection with Schistosoma mansoni in occupationally exposed adults and effect of HIV-1 co-infection on susceptibility to schistosomiasis: a longitudinal study. *Lancet* 2002; **360**:592–596.
  105. Hung CC, Chen PJ, Hsieh SM, Wong JM, Fang CT, Chang SC & Chen MY. Invasive amoebiasis: an emerging parasitic disease in patients infected with HIV in an area endemic for amoebic infection. *AIDS* 1999; **13**:2421–2428.
  106. Amarapurkar DN, Chopra KB, Phadke AY, Sahni S, Prabhu SR & Kalro RH. Tuberculous abscess of the liver associated with HIV infection. *Indian Journal of Gastroenterology* 1995; **14**:21–22.
  107. Pottipati AR, Dave PB, Gumaste V & Vieux U. Tuberculous abscess of the liver in acquired immunodeficiency syndrome. *Journal of Clinical Gastroenterology* 1991; **13**:549–553.
  108. Kielhofner MA & Hamill RJ. Focal hepatic tuberculosis in a patient with acquired immunodeficiency syndrome. *The Southern Medical Journal* 1991; **84**:401–404.
  109. Kramer JR, Giordano TP, Soucek J, Richardson P, Hwang LY & El-Serag HB. The effect of HIV coinfection on the risk of cirrhosis and hepatocellular carcinoma in U.S. veterans with hepatitis C. *The American Journal of Gastroenterology* 2005; **100**:56–63.
  110. Poles MA, Lew EA & Dieterich DT. Diagnosis and treatment of hepatic disease in patients with HIV. *Gastroenterology Clinics of North America* 1997; **26**:291–321.
  111. Parkin DM, Wabinga H, Namboze S & Wabwire-Mangen F. AIDS-related cancers in Africa: maturation of the epidemic in Uganda. *AIDS* 1999; **13**:2563–2570.
  112. Chokunonga E, Levy LM, Bassett MT, Borok MZ, Mauchaza BG, Chirenje MZ & Parkin DM. Aids and cancer in Africa: the evolving epidemic in Zimbabwe. *AIDS* 1999; **13**:2583–2588.
  113. Newton R, Ziegler J, Beral V, Mbidde E, Carpenter L, Wabinga H, Mbulaiteye S, Appleby P, Reeves G, Jaffe H & Uganda Kaposi's Sarcoma Study Group. A case-control study of human immunodeficiency virus infection and cancer in adults and children residing in Kampala, Uganda. *International Journal of Cancer* 2001; **92**:622–627.
  114. Gottesman D, Dyrszka H, Albarran J & Hilfer J. AIDS-related hepatic Kaposi's sarcoma: massive bleeding following liver biopsy. *The American Journal of Gastroenterology* 1993; **88**:762–764.
  115. Wilcox CM & Monkemuller KE. Hepatobiliary diseases in patients with AIDS: focus on AIDS cholangiopathy and gallbladder disease. *Digestive Diseases* 1998; **16**:205–213.
  116. Walden DT. Biliary problems in people with HIV disease. *Current Treatment Options in Gastroenterology* 1999; **2**:147–153.
  117. Alvarez OA, Vanegas F, Maze GL, Gross GW & Lee M. Polymicrobial cholangitis and liver abscess in a patient with the acquired immunodeficiency syndrome. *The Southern Medical Journal* 2000; **93**:232–234.
  118. Daly CA & Padley SP. Sonographic prediction of a normal or abnormal ERCP in suspected AIDS related sclerosing cholangitis. *Clinical Radiology* 1996; **51**:618–621.
  119. Ko WF, Cello JP, Rogers SJ & Lecours A. Prognostic factors for the survival of patients with AIDS cholangiopathy. *The American Journal of Gastroenterology* 2003; **98**:2176–2181.

---

Received 27 June 2005, accepted 28 October 2005